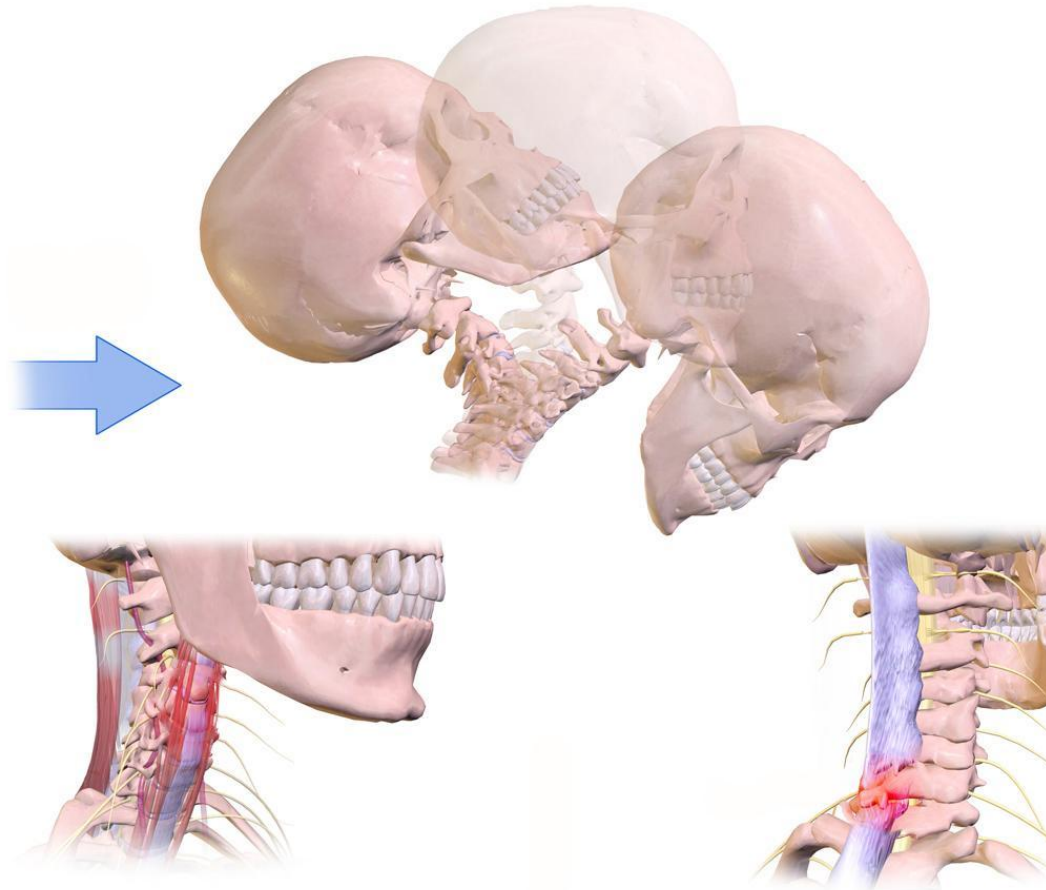

Whiplash

Fiona Rattray & Linda
Ludwig Pg.379

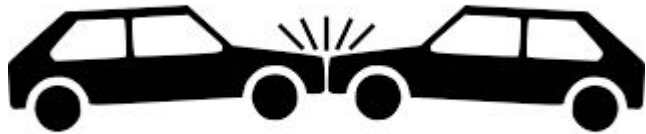WHIPLASH

- ▶ H.E Crowe identified the syndrome “**whiplash**” as neck injuries reported by motorists following automobile accidents. (MVA)
- ▶ Military pilots experienced catapult-assisted takeoffs from aircraft carriers
- ▶ Whiplash is used to describe both the injury itself and the mechanism of the injury.
- ▶ It’s also used to describe unrelated clinical symptoms that appear following the injury, such as HA’s, dizziness, and TMJ disorders.
- ▶ Rear impact collisions result in long term symptoms, cervical sprains, cervical strains, HA’s of cervical origins, cervical herniated disc’s, and sprained cervical facet joints.

CAUSES OF WHIPLASH

- ▶ **Whiplash is an acceleration-deceleration injury to the head and neck**
- ▶ **Usually resulting of vehicular collision**
- ▶ **Possible in contact or high speed sports**

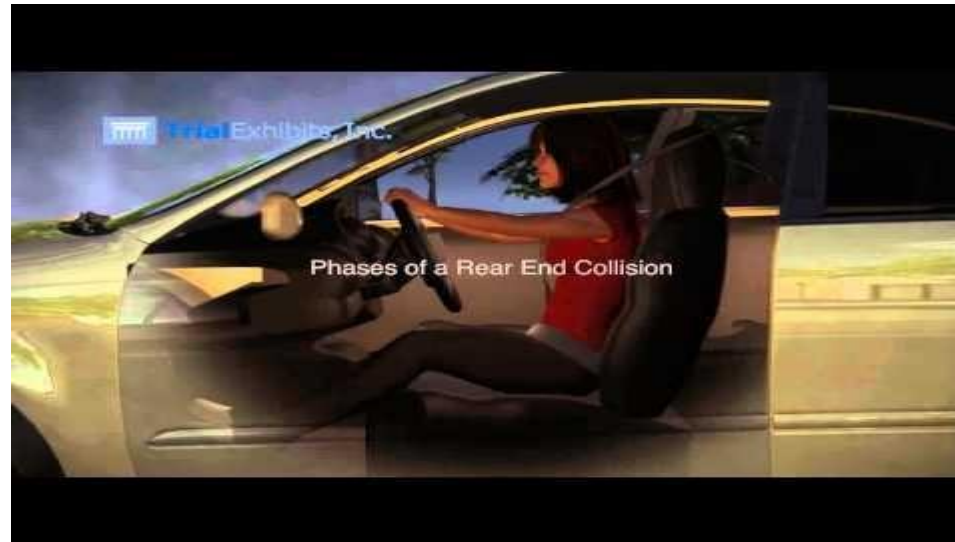CONTRIBUTING FACTORS



- ▶ The accident itself may activate TP's in SCM, and many other neck structures.
- ▶ Resulting in dizziness with rotation of their head quickly, which makes it hard to drive, checking blind spots.

REAR IMPACT

- ▶ More severe long lasting symptoms
- ▶ Most researched
- ▶ Mild SCM strains to severe longus Colli muscle tears
- ▶ Less common: Rupture of Anterior Longitudinal Ligament, avulsions of cervical intervertebral discs
- ▶ There are **4 Phases** of Rear Impact Whiplash



Phase 1 (60 milliseconds)

- ▶ the vehicle is struck from behind
- ▶ the back of the seat pushes into the person's torso
- ▶ the person's torso initially is compressed into the seat back, then is carried forward.
- ▶ the head stays fixed in place due to inertia
- ▶ the torso then moves abruptly upwards, compressing the cervical spine

Phase 2 (120 milliseconds)

- ▶ The vehicle and torso reach their peak forward acceleration
- ▶ The seat back begins to recoil
- ▶ The head and neck stay in place as the torso moves forward
- ▶ The neck goes into hyperextension
- ▶ A shear force occurs between the cervical spine and the thoracic spine
- ▶ The rising torso creates some slack in the shoulder and lap belt
- ▶ The anterior neck muscles and ligaments are overstretched and the facet and temporomandibular joints may be injured at this point

Phase 3 (160 milliseconds)

- ▶ The head and neck are now at their peak forward acceleration while the vehicle and torso are slowing down
- ▶ Slack created in the shoulder and lap belt will increase the forward motion of the torso, neck and head

Phase 4 (280 milliseconds)

- ▶ The head and torso are now at full deceleration
- ▶ The shoulder harness eventually restrains the torso while the head and neck continue to flex forward.
- ▶ The head moves into hyperflexion
- ▶ The greatest amount of stress is placed on the muscles, discs and ligaments of the lower cervical and upper thoracic spine, injuring these tissues with C5 to C7 most frequently affected.

Other factors affecting Rear Impact Whiplash

- ▶ Head position
- ▶ Seat belts
- ▶ Headrest position
- ▶ Seat positioning
- ▶ Stature
- ▶ Airbags

FRONT IMPACT

- ▶ Reverse of rear-impact collision
- ▶ Torso accelerate backward, neck hyperflexes then hyper-extends



SIDE IMPACT

- ▶ Initial lateral flexion of the neck and torso towards the side of the striking vehicle
- ▶ Lumbar and thoracic spine may experience side bending
- ▶ Ligaments and discs may be affected
- ▶ Cervical and upper Thoracic spine may also be affected



TISSUES INVOLVED IN ANY WHIPLASH

- ▶ Neck, upper thorax and head
- ▶ Cervical and thoracic vertebrae, intervertebral discs
- ▶ Facet jts, jt capsules and ligaments, TMJ jts
- ▶ Ant & Post longitudinal ligaments
- ▶ Lymphatics, fascia, blood vessels, cranial, cervical and thoracic nerve roots

CLASSIFICATION OF WHIPLASH

- ▶ Stephen Foreman, DC and Arthur Croft, DC published a classification system in 1988 based on the **severity of the injury, stage of healing and type of collision**
- ▶ **Grade 1 or minimal:** There is no limitation of motion; no ligamentous injury; no neurological findings
- ▶ **Grade 2 or Slight:** There is limitation of motion; no ligamentous injury; no neurological findings
- ▶ **Grade 3 or Moderate:** There is limitation of motion; some ligamentous injury; neurological findings may be present

FOREMAN AND CROFT CLASSIFICATION

- ▶ **Grade 4 or Moderate or Severe:** There is limitation of motion; ligamentous instability; neurological findings are present; fracture or disc derangement is present.
- ▶ **Grade 5 or Severe:** The injury requires surgical management or stabilization.
- ▶ **Stage 1:** Acute injury, inflammation phase, up to 72 hours post-accident.
- ▶ **Stage 2:** Subacute, repair phase, 72hours to 14 weeks.
- ▶ **Stage 3:** Remodelling phase, 14 weeks to 12 months or more.
- ▶ **Stage 4:** Chronic, permanent.
- ▶ **Type 1 Collision:** Rear impact
- ▶ **Type 2 Collision:** Side impact
- ▶ **Type 3 Collision:** Front impact

MEDICAL TX OF WHIPLASH

- ▶ Acute whiplash with suspected fracture or dislocation will receive X-ray assessment.
- ▶ C/sp support collar, Ice, medications (analgesics or mm.relaxants)
- ▶ Sub-acute or chronic: when symptoms don't resolve, most are referred to Physiotherapy, Chiropractor, and of course Massage Therapy 😊

LEGAL IMPLICATIONS FOR MT'S TREATING WHIPLASH

- ▶ 24 hrs following the accident, clients may have few symptoms, so severity may not be present.
- ▶ Dislocation, fractures, radicular symptoms, extreme muscle weakness, or difficulty swallowing REFER TO PHYSICIAN.
- ▶ Therapist must preform a thorough assessment.
- ▶ Documentation is important, why?
- ▶ You may be required to go to court.
- ▶ **Releasing files:** Must be done ONLY if you have written CONSENT from your client.

SYMPTOMS OF ACUTE WHIPLASH

- ▶ Muscles of neck may suffer, spasm, strains and contusions
- ▶ Facet jt irritation, cervical ligament sprains, hematomas
- ▶ Ruptures, cervical disc lesions, facet dislocations
- ▶ Dislocation or fractures: Vertebrae are surgically treated and immobilized with wires, pins, screws or plates.
- ▶ Loss of consciousness, post concussion HA's
- ▶ Seat belt injury and knee's may be affected by hitting the dashboard
- ▶ Heat, edema, and spasms can develop muscle guarding, tenderness at injury site
- ▶ Neuro Involvement: Peripheral nerve injury, loss of strength and mm.atrophy within 72hrs.

EARLY SUB-ACUTE

- ▶ Edema, heat, inflammation
- ▶ P has decreased within muscles injured
- ▶ Tenderness
- ▶ Protective mm. spasms and Tp's
- ▶ Adhesions are developing at site
- ▶ ROM is reduced
- ▶ Neurological signs: Numbness and tingling in arms are a potential

LATE SUB-ACUTE

- ▶ P, edema and inflammation are decreasing.
- ▶ SCM, longus colli are becoming less tender.
- ▶ ROM is improving from the acute stage, still reduced.
- ▶ Protective muscle is now replaced by increased mm.tone in affected mm's.
- ▶ Tp's developing in compensatory mm's and affected muscles.
- ▶ Adhesions are maturing around the injury.

CHRONIC

- ▶ P is deep, achy, and vague.
- ▶ HA's may increase with activity.
- ▶ Large C/sp muscle groups are shortened and fibrosed.
- ▶ Hypertonicity, TP's, and spasms are potentials.
- ▶ TMJ issues, Hypertonicity of mastication musculature.
- ▶ Tissues may be cool due to ischemia.
- ▶ Full ROM is reduced, strength is reduced, and possible disuse atrophy.
- ▶ Long term injuries that may develop: OA, DDD of C/sp.

OBSERVATIONS

- ▶ Acute
- ▶ There may be little to observe immediately following the injury
- ▶ Over 24 - 48 hours there may be an antalgic posture or head forward posture
- ▶ The client may have a pained or medicated facial expression
- ▶ Edema may develop at the lesion site with some redness
- ▶ Bruising may be visible over the injury site
- ▶ With a Grade 2 or higher injury there may be a visible gap in the contour of SCM
- ▶ A cervical support collar may be worn

- ▶ Early and Late Subacute
- ▶ Head forward posture
- ▶ Pained or medicated facial expression may still be present
- ▶ Edema diminishes
- ▶ Bruising changes color
- ▶ With a grade 2 or above a gap is still apparent in the SCM

- ▶ Chronic
- ▶ Head forward posture may still be present
- ▶ SCM assumes a more vertical orientation
- ▶ Scapulae may be protracted

Palpation

- ▶ Acute
 - ▶ Heat is present over the injured tissues
 - ▶ Tenderness is present local to the injury site
 - ▶ Texture of the edema is firm
 - ▶ With a Grade 2 or higher a palpable gap in SCM contour is present and protective muscle spasm is present in the affected muscles, the synergists and the antagonists
- ▶ Subacute
 - ▶ The temperature over the site drops
 - ▶ Point tenderness is present local to the injury site
 - ▶ Edema is less firm
 - ▶ Adhesions, hypertonicity and trigger points are present

- ▶ Chronic
- ▶ Injury site may be cool due to ischemia
- ▶ Point tenderness occurs local to the injury site, the muscles of mastication and the thorax
- ▶ Adhesions are present
- ▶ Thickening and scarring of the muscles occurs and crepitus may be present
- ▶ Palpable gap may still be present in SCM
- ▶ Hypertonicity and trigger points local to the injured muscles
- ▶ Disuse atrophy

TESTING-ACUTE STAGE

- ▶ Symptoms develop 28-48 hrs
- ▶ Little P and decrease ROM
- ▶ AF ROM is reduced due to P
- ▶ Grade 2 or higher: NO neuro testing, deep tendon reflexes, sensory or motor testing, swallowing test are CI'd. Refer to PHYSICIAN
- ▶ PR ROM is allowed for grade 1
- ▶ AR Isometric testing is allowed for grade 1
- ▶ Performing all painful ranges LAST

EARLY & LATE SUB-ACUTE

- ▶ **AF ROM:** Neck is limited due to P
- ▶ **PR ROM:** Tissue stretch is felt, stretching painful ranges LAST, capsular restriction is potential if facet jts were injured.
- ▶ **AR Isometric testing & AR strength tests of Grade 2 or higher:** Weakness + P in Rhomboids, middle traps, anterior and anterolateral/posterolateral neck flexors.

CHRONIC

- ▶ **AF ROM:** Painfully limited as much as 50%
- ▶ **PR ROM:** Pain full ranges must be tested LAST. Mild painful tissue stretch.
- ▶ Capsular restriction is present in C/sp of ligaments and facet jts that were injured.
- ▶ **AR strength testing:** decreased strength of grade 2 or higher

SPECIAL TESTS

- ▶ VAT test also known as VBI
- ▶ Swallowing test
- ▶ Sensory testing
- ▶ Deep tendon reflexes: C5-C7
- ▶ Strength testing
- ▶ Upper Limb tension testing
- ▶ Spurling's, Cervical Compression, Cervical distraction
- ▶ TOS test's: Adsons, Edens, etc

CONTRAINDICATIONS

- ▶ Grade 2 Acute stage: PF and AROM and neuro testing
- ▶ VAT (VBI) is positive
- ▶ Avoid removing any protective mm splinting of acute whiplash
- ▶ No passive stretching done on muscle spasms
- ▶ Jt play for the spine should not be painful
- ▶ Avoid aggressive techniques in sub-acute and chronic stages to avoid flare up's
- ▶ Frictions are CI'd if taking anti-inflammatory or blood thinners

ACUTE STAGE TREATMENT

TX GOALS

- ▶ Decrease pain
- ▶ Decrease SNS firing
- ▶ Reduce inflammation
- ▶ Reduce edema

Treatment

- ▶ DDB, treat compensatory structures first
- ▶ Lymphatic drainage
- ▶ Grade 1 whiplash: Isometric agonist contraction to antagonists, Vibrations and effleurage to non affected area.
- ▶ GTO and O&I indicated on affected tendons.
- ▶ Specific work (on site) is CI'd at this time.
- ▶ Stroking and muscle squeezing: Head and muscles of mastication and distal arms of all grades.

EARLY SUB-ACUTE

Tx Goals

- ▶ Healing is still fragile, address tx with care
- ▶ Reduce inflammation
- ▶ Reduce P
- ▶ Reduced edema
- ▶ Prevent adhesion formation
- ▶ Reduce spasms

Treatment

- ▶ Proximal lymph drainage
- ▶ Treat compensatory structures first
- ▶ Trunk + shoulder tx: Eff, Petrissage, palmar kneading's, C-scooping, finger tip kneading's and O & I to compensatory structures and proximal to the injury site are allowed
- ▶ GTO to SCM, scalenes, Upp traps, Levator scap and pos cervical mm's

EARLY SUB-ACUTE

- ▶ TP's are tx'd using mm.stripping or intermittent ischemic compressions, without disturbing the injury site.
- ▶ **Grade 1**-On site work is tolerated within P tolerance
- ▶ **Grade 2 or higher**- On site is restricted to light stroking and vibrations
- ▶ Careful P free mid range PR ROM at C/sp and BL scaps
- ▶ Head musculature, muscles of mastication and BL arms are tx'd

LATE SUB-ACUTE

Tx Goals

- ▶ Reduce P
- ▶ Decrease SNS firing
- ▶ Reduce edema
- ▶ Reduce H⁺ and TP's in the neck and shoulder muscles

Treatment

- ▶ Positioning: Side lying or prone, secure head and neck accordingly
- ▶ Hydro: Cold/Hot contrast to injury site
- ▶ *If inflammation occurs, return to cold
- ▶ Tx compensatory structures first
- ▶ Prone position: Tx suboccipitals with GTO

LATE SUB-ACUTE

- ▶ Supine: General tx to compensatory structures
- ▶ Affected side: SCM pincer grasp (side bend and rotate to side being tx'd)
- ▶ Tx one side at a time, why? *Carotid artery
- ▶ Tx Infra and supra hyoids mm's *Very gently here as client may feel choked
- ▶ Tx anterior region for H+ and TP's, Pec major + minor, subclavius, rotator cuff mm's, intercostals, and diaphragm
- ▶ Grade 2-3: On site work focuses on decreasing adhesions, skin rolling, muscle stripping, and frictions within P tolerance
- ▶ Passive stretch post frictions: 30 secs, than Ice up to 5 mins
- ▶ Jt play techniques are used to restore ROM: Long axis traction
- ▶ Mid-full range passive relaxed ROM of C/sp is indicated.

CHRONIC

Tx Goals

- ▶ Reduce SNS firing
- ▶ Reduced H+ and TP's in the neck and shoulder musculature
- ▶ Reduce adhesions
- ▶ Restore ROM
- ▶ Increase local circulation

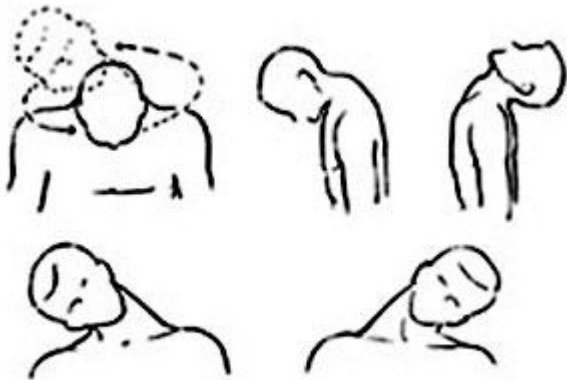
Treatment

- ▶ Positioning: Chosen based on the clients tolerance, prone, side lying, supine are indicated
- ▶ Hydro: Moist heat
- ▶ Tx compensatory structures
- ▶ Shoulder girdle is tx'd for H+ and TP's using kneadings, mm stripping, and fascial techniques
- ▶ Cross frictions on remaining adhesions: Passive stretch for 30 secs than Ice up to 5 mins

CHRONIC

- ▶ Joint play at C/sp, thorax and shoulders
- ▶ All done with long axis traction: holding 10 sec/3x
- ▶ Shoulder girdle and neck musculature treated with GSM
- ▶ DDB for relaxation

SELF-CARE



Neck Exercise

- ▶ DDB
- ▶ Hydro: Choose based on which stage of healing
- ▶ Self massage in late sub-acute and chronic: Skin rolling and mm stripping
- ▶ Remex: Depends on stage of healing
- ▶ Acute: Gradually increase ROM and strength, side bending, rotation, flexion and extension
- ▶ Acute & Sub acute: AROM of neck
- ▶ Late sub acute: AROM is gradually increased, Isometric exercises for posterior C/sp mm are introduced
- ▶ Resisting side bending (Scalenes)
- ▶ Resisting extension (posterior mm)

SELF-CARE

- ▶ Aerobic exercise will strengthen neck musculature, why?
- ▶ Many muscle's are accessory muscles of respiration
- ▶ Chronic: Gradually increase to isotonic active resisted for posterior and lateral muscles
- ▶ Neck and T/sp extensors are strengthened in prone position (Rhomboids, mid traps and erectors)

SELF-CARE

- ▶ Chin tucks to stretch sub occipitals 30-3-3
- ▶ Scalene + Upp traps stretching 30-3-3
- ▶ Refer to Physio, Chiro, Acupuncture, and or Osteopathy
- ▶ Shorter more frequent Tx's in Acute and early sub acute: 2/30 mins for 3 weeks, Re-Ax each week
- ▶ As client improves, 1x/week in late sub acute, RE-AX after 6 weeks, if client is not improving with Grade 1 refer out after 6 weeks, grade 2 or higher refer out after 12weeks