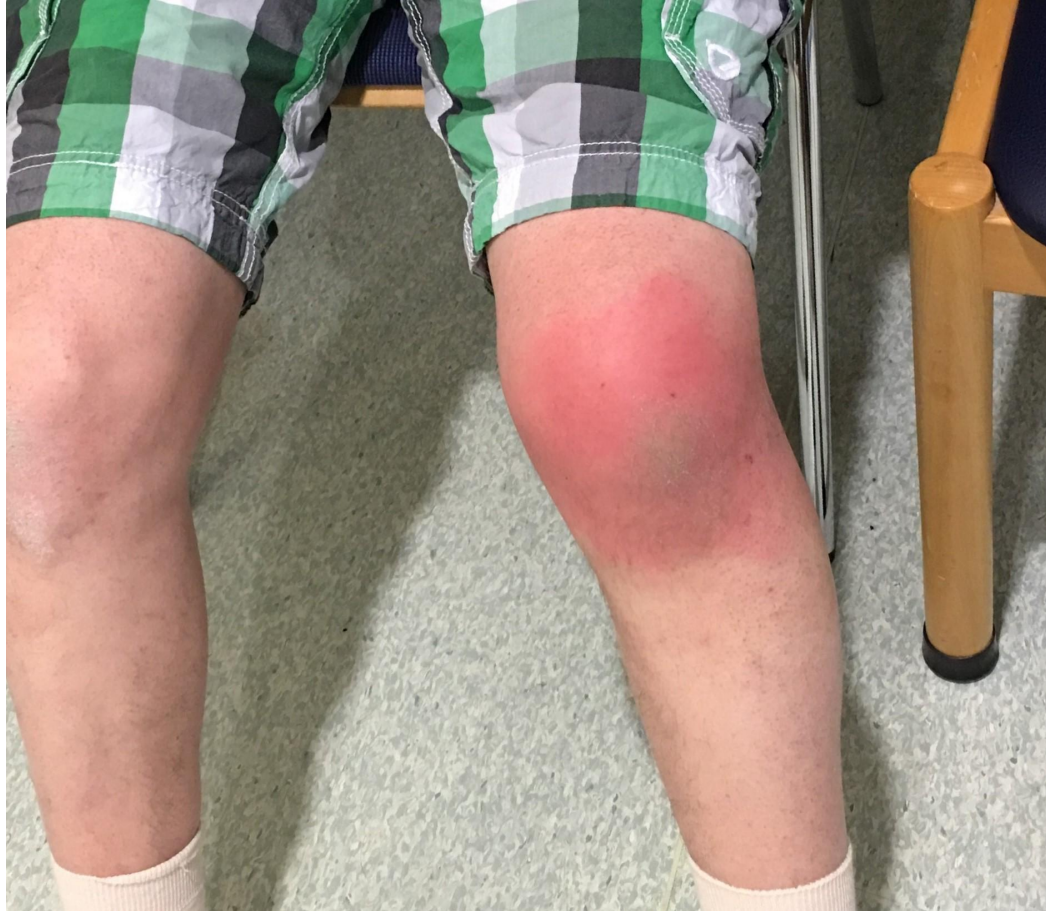


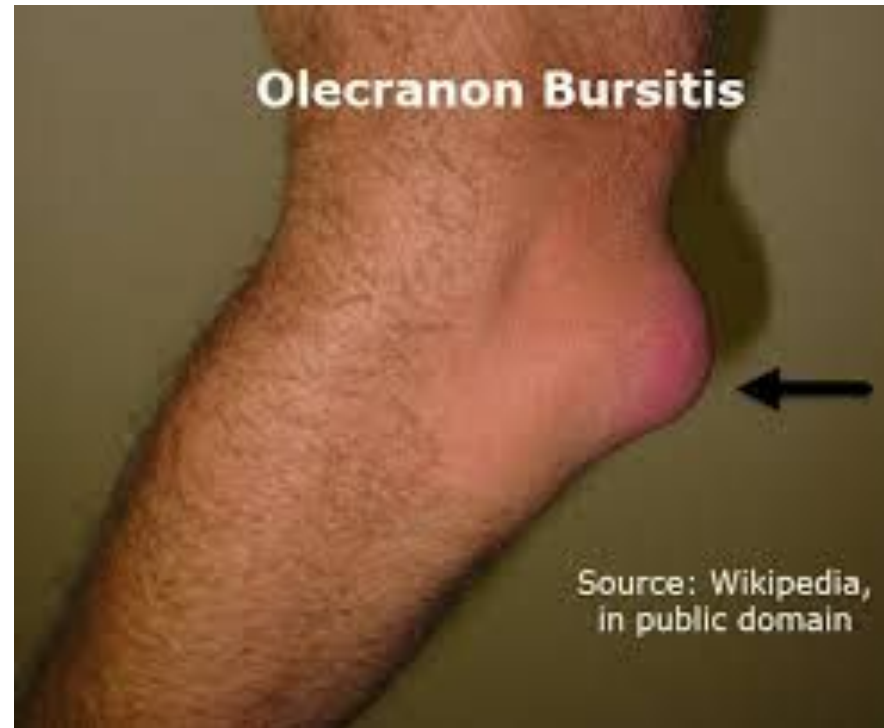
# BURSITIS

Fiona Rattray & Linda  
Ludwig Pg. 449

# BURSITIS

- ▶ Bursitis is inflammation of a bursa.
- ▶ Is a small, flat, sac lined with synovium. Both membranes surfaces of the bursa are normally in contact, separated by only a thin film of lubricating fluid.
- ▶ Reduces friction between tendons and bones
- ▶ It is flat, a bursa is not palpable unless its inflamed.
- ▶ Bursas can regrow in 6-24 month period if surgically removed.



# CAUSE



- ▶ **Overuse:** Excessive friction and inflammation of bursal wall. Bursitis is usually secondary to other conditions.
- ▶ **Contributing factors:** MM imbalances, poor biomechanics, postural dysfunctions.
- ▶ **Less common:** Acute trauma, infection and pathologies such as OA, RA and Gout.

# COMMON LOCATIONS & CAUSES



- ▶ Shoulder Bursae
- ▶ Several bursa at the shoulder
- ▶ **Subacromial (Subdeltoid) bursa**, lies between acromion and supraspinatus tendon, portion between the deltoid muscle and the humerus.
- ▶ This bursa is palpated through the anterior deltoid muscle near the acromion.

# SHOULDER BURSAE

- ▶ **Subscapularis bursa** lies between the scapula and subscapularis muscle, it is not easily palpable.
- ▶ **Subacromial bursitis** is part of shoulder impingement syndrome. The bursa is painfully irritated as its compressed between the rotator cuff tendons, coracoacromial ligament and the acromion or the bicep tendons.
- ▶ Overuse of the shoulder and overhead positioning is the most common cause.
- ▶ Acute calcific tendinitis leading to bursitis leads to severe shoulder pain that increases with movement.

## Olecranon Bursitis

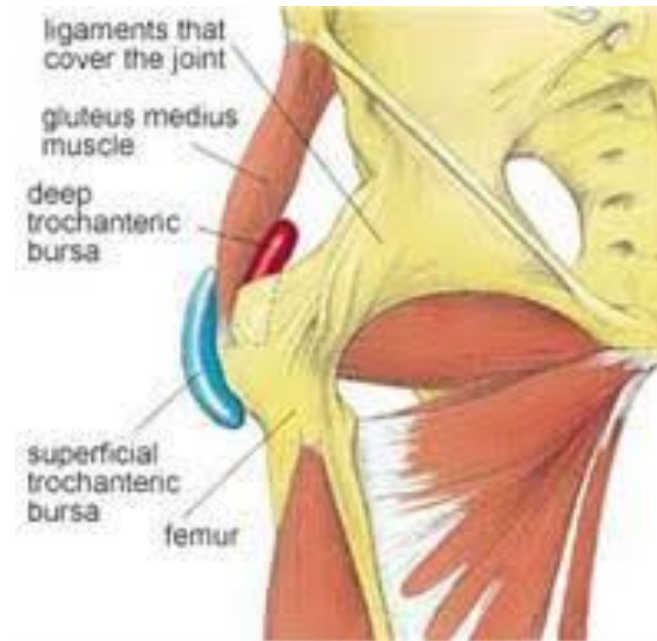# OLECRANON BURSA

- ▶ Olecranon bursa lies between the olecranon and the subcutaneous fascia.
- ▶ Very noticeable while swollen and inflamed.
- ▶ Usually irritated by repetitive weight bearing or trauma, such as dragging the elbow on the ground.

Source: W  
in public

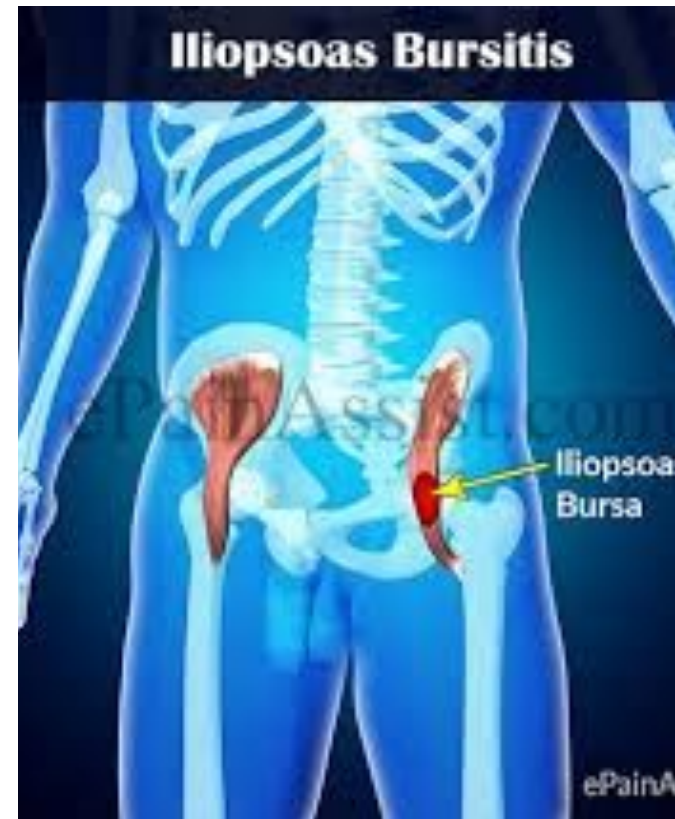# TROCHANTERIC BURSA

- ▶ There are 2 main bursae at the greater trochanter.
- ▶ One lies between the gluteus maximus tendon and the trochanter.
- ▶ The other is between the gluteus Medius tendon and the trochanter.
- ▶ The bursae are palpated through the overlying gluteus maximus tendons.
- ▶ P is local to the lateral hip, and the client will not be able to sleep on the affected side.
- ▶ P is worse on climbing stairs and getting out of a car.
- ▶ Causes are altered hip biomechanics, due to leg length discrepancy, low back P causing antalgic gait, OA, and surgery.
- ▶ Repetitive actions and ITB contracture also causes friction of the bursa.

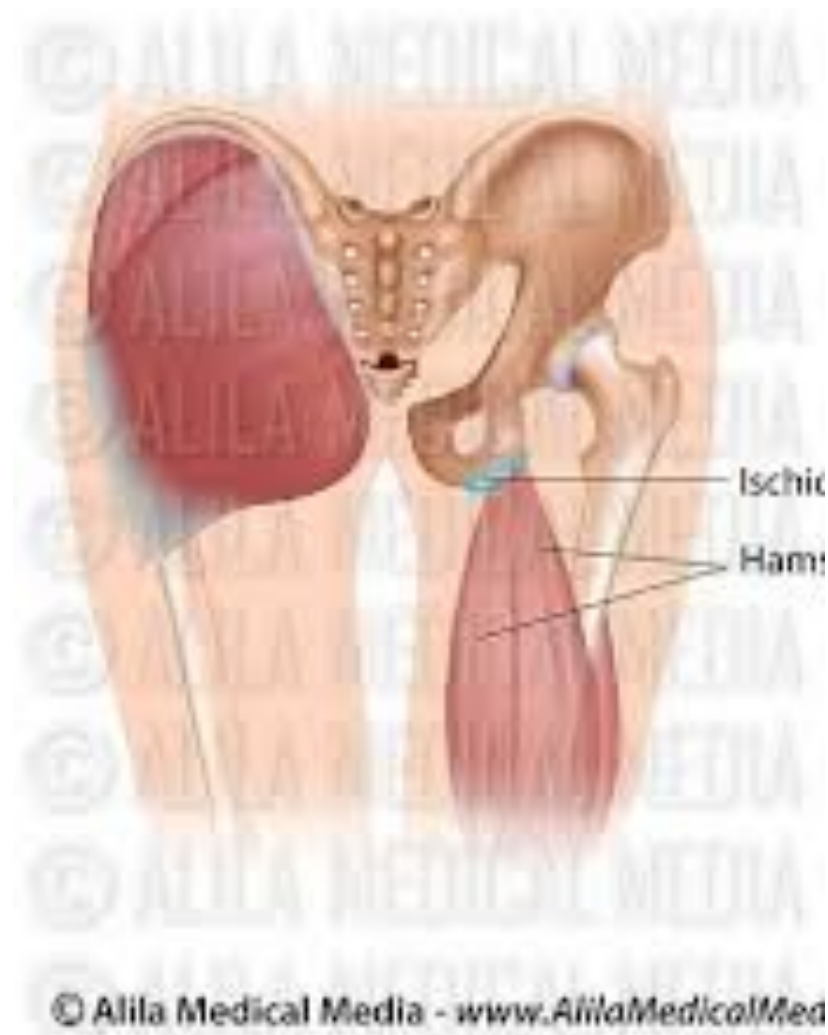

# ILIOPECTINEAL BURSA

- ▶ Iliopectineal bursa lies between the iliopsoas muscle and the iliofemoral ligament.
- ▶ To palpate the bursa, the client lays supine with hip flexed to 90 degrees, the bursa is located one-two cm inferior to the middle third of the inguinal ligament.
- ▶ P is at the anterior hip and may radiate down the anterior leg due to pressure on the femoral nerve.
- ▶ Antalgic posture is hip flexion and external rotation.
- ▶ Bursitis is caused by hip flexor tightness and repetitive activity.

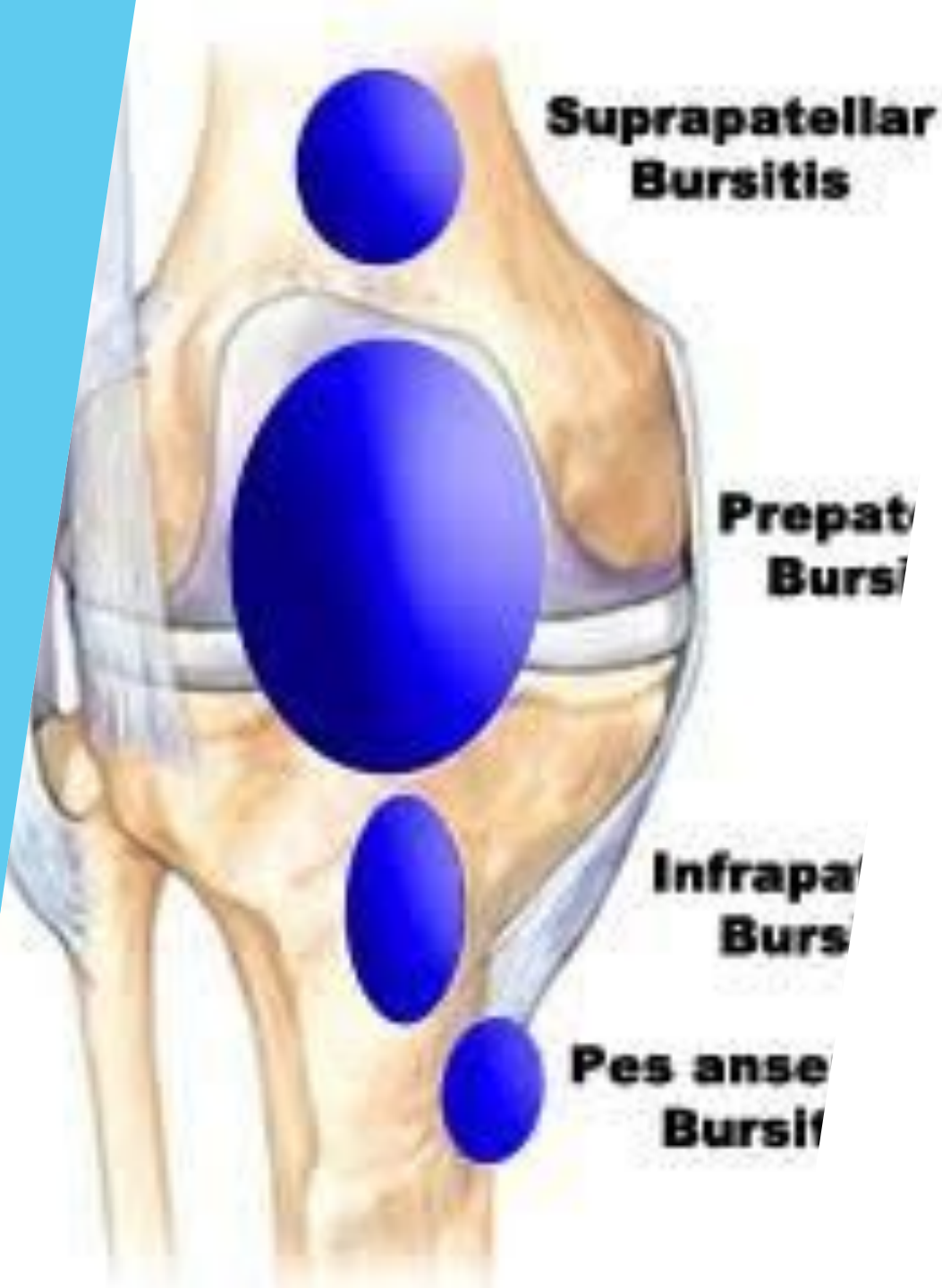


# ISCHIAL BURSA

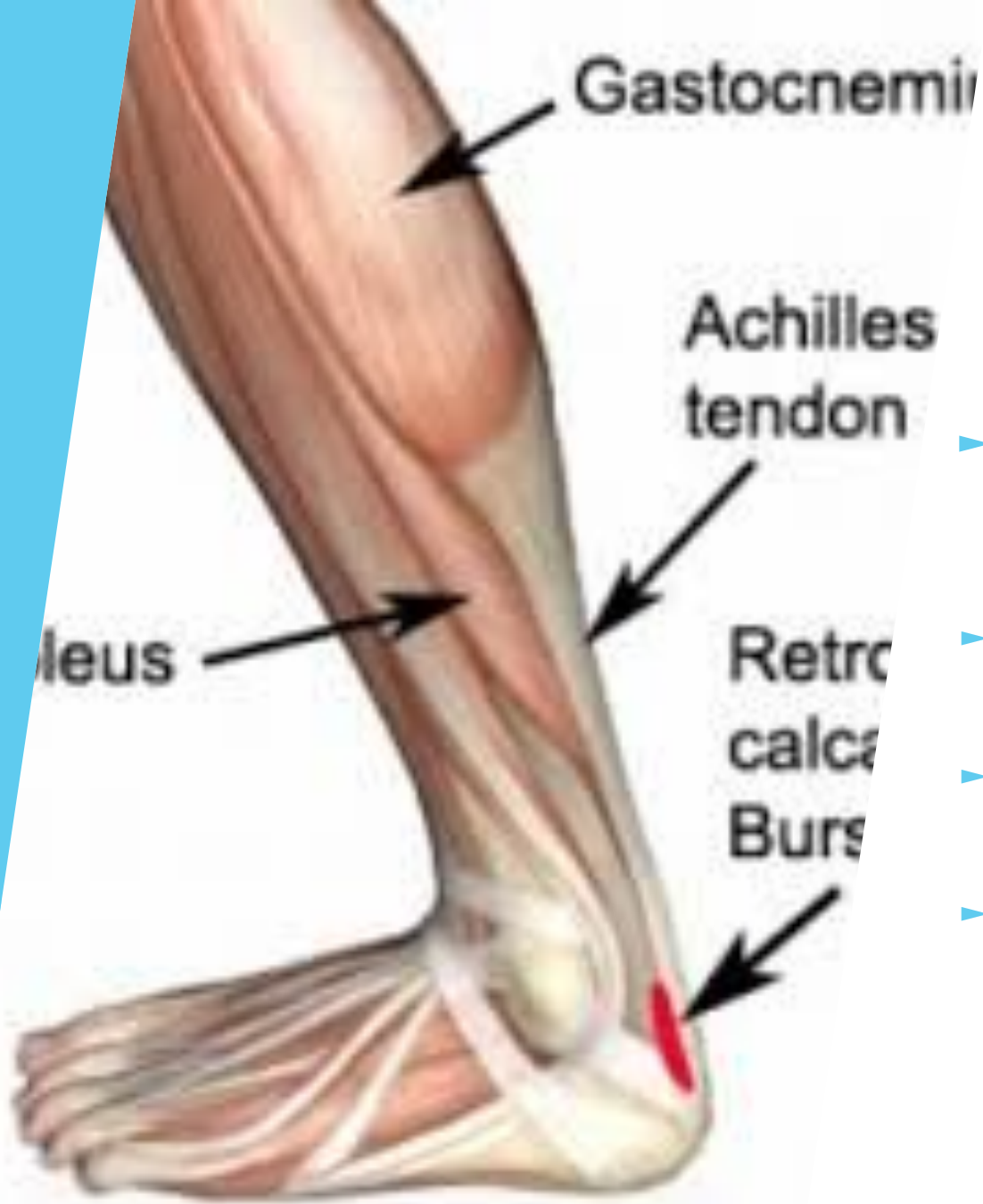

- ▶ **Ischial bursa** lies between gluteus maxims and ischial tuberosity.
- ▶ It is palpated through the gluteus maximus.
- ▶ If inflammation is present, well localized P over the ischial tuberosity.
- ▶ There may be referral down the posterior leg that mimics sciatic P.
- ▶ Antalgic gait, when the client leans towards the affected side and shortening their stride.
- ▶ Standing on toes may be painful.
- ▶ May be caused by sitting for a long time on a hard surface.
- ▶ Excessive sprinting may be the cause due to hamstring contraction.

# KNEE BURSA



- ▶ There are numerous bursae around the knee.
- ▶ The **pes anserine bursa** lies between the tendons of sartorius, gracilis, and semitendinosus muscles and medial tibia.
- ▶ The **infrapatellar bursa** lies between the patellar ligament and tibia.
- ▶ Others lie between IT band, lateral collateral ligament and tibia.
- ▶ All bursae are palpated through the over lying tendons.
- ▶ P is worse with use, more so running or cycling causing inflammation.
- ▶ The **prepatellar bursa** lies between the lower half of the patella, the patellar ligament and skin. Easily palpated when inflamed and is locally painful.

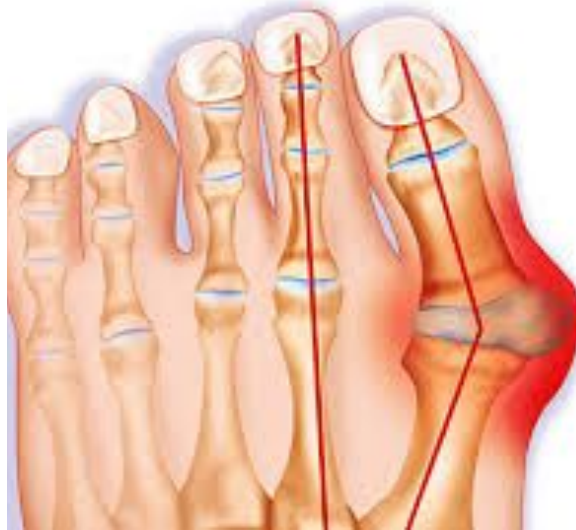
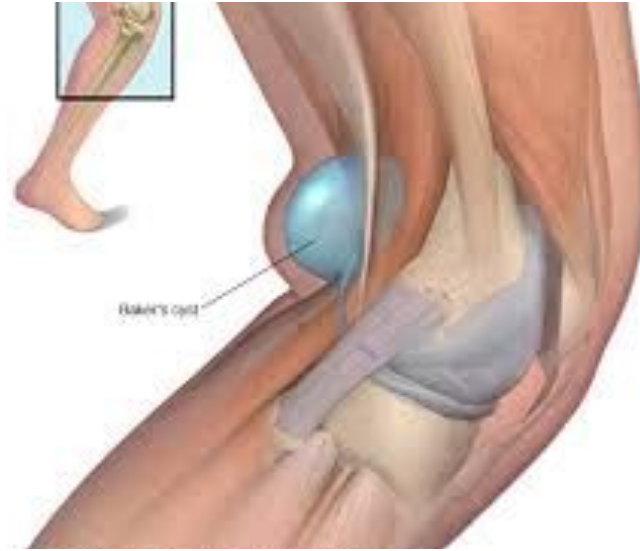
## RETROCALCANEAL BURSA

- ▶ Retrocalcaneal bursa lies between the Achilles tendon and the calcaneus.
- ▶ It is palpated on either side of the tendon.
- ▶ Locally painful when inflamed.
- ▶ Overuse and a tight gastrocnemius-soleus complex are cause of inflammation.

# OTHER BURSAL INJURIES

- ▶ **Baker cyst** is a synovial cyst that usually appears at the lateral side of the popliteal space.
- ▶ Baker cysts can appear in children and adults.
- ▶ A **bunion** occurs at the first metatarsophalangeal joint capsule.
- ▶ A bunion is formed by excessive bone growth, a callus and an inflamed, thickened bursa forming over the joint.



# SYMPTOM PICTURE ACUTE

- ▶ Bursitis secondary to overuse is a chronic condition with an initial, acute inflammatory stage.
- ▶ Bursa is compressed and irritated.
- ▶ Inflammation, heat and swelling.
- ▶ Pain is deep and burning at rest or activity.
- ▶ Pain may interrupt sleep.
- ▶ ROM of the affected joint is restricted.
- ▶ Other conditions may be present.

# SYMPTOM PICTURE CHRONIC

- ▶ P or achiness is felt with activity or upon direct compression.
- ▶ P is more localized to the bursa.
- ▶ Chronic inflammation, fibrosis, and adhesions are present.
- ▶ ROM of the joint is less restricted than the acute stage.

# CONTRAINDICATIONS

- ▶ Acute bursitis avoid compressing the bursa or apply techniques that place a drag on the tissues.
- ▶ On site techniques are CI'd with acute bursitis.

\*\* Please read Observation & Palpation Pg.453, make point form notes on what you will observe and palpate in the Acute and Chronic stage.

# ACUTE TREATMENT

- ▶ **Positioning:** is for comfort so the bursa is not compressed. The limb should be elevated.
- ▶ **Hydro:** Is cold to the affected bursa, such as a frozen towel. Should be a light material that wouldn't compress the bursa.
- ▶ Treat compensatory structures, DDB
- ▶ Lymphatic drainage techniques are applied proximal to the affected area.
- ▶ Swedish techniques to proximal limb, effleurage and petrissage.
- ▶ TP's are treated in the proximal limb with mm stripping and gentle ischemic compressions.
- ▶ GTO and O & I techniques are used only to the attachments that are not local to the bursa.

# ACUTE TREATMENT

- ▶ Segmental petrissage are used towards the bursa, do not put drag on the bursa.
- ▶ No on-site work.
- ▶ Gentle joint play is used to decrease mm spasms that surround the bursa.
- ▶ Stroking and gentle mm squeezing are applied distal to the area.
- ▶ Pain Free Passive relaxed and Active assisted ROM interspersed through out the treatment.

# CHRONIC TREATMENT

- ▶ **Positioning:** is for comfort so the bursa is not compressed. The limb should be elevated.
- ▶ **Hydro:** Deep moist heat. Contrast application is used after treatment to increase circulation.
- ▶ Treat compensatory structures, DDB
- ▶ Fascial techniques to treat mm's crossing the bursa: Skin rolling, cross hand spreading and finger tip spreading.
- ▶ Swedish techniques are used, effleurage and petrissage to agonists and antagonists.
- ▶ TP's are treated with mm stripping.

# CHRONIC TREATMENT

- ▶ PF passive relaxed ROM of the affected joints are interspersed.
- ▶ Frictions to adhered structures surrounding the bursa. Followed by a stretch for 30 sec and Ice up to 5 mins.
- ▶ Repetitive effleurage and petrissage are used on the distal limb.
- ▶ Joint play is indicated for any hypomobile joints.
- ▶ Treatment is finished with effleurage to the entire limb.

# SELF-CARE

- ▶ **Acute stage:** rest, ice and elevate the affected limb.
- ▶ Pain free AROM and isometric exercises are indicated as soon as the client can tolerate them.
- ▶ **Chronic stage:** Rest from aggravating activities, return to activity is gradual.
- ▶ If flare up of acute symptoms occur, readdress with Ice.
- ▶ Self massage is performed to mm's surrounding bursa. Stretching is indicated.
- ▶ The client gradually progresses to Isotonic exercises.
- ▶ The goal is to restore painless, full ROM and strength.
- ▶ Refer out for orthotics is needed and or Physiotherapy.