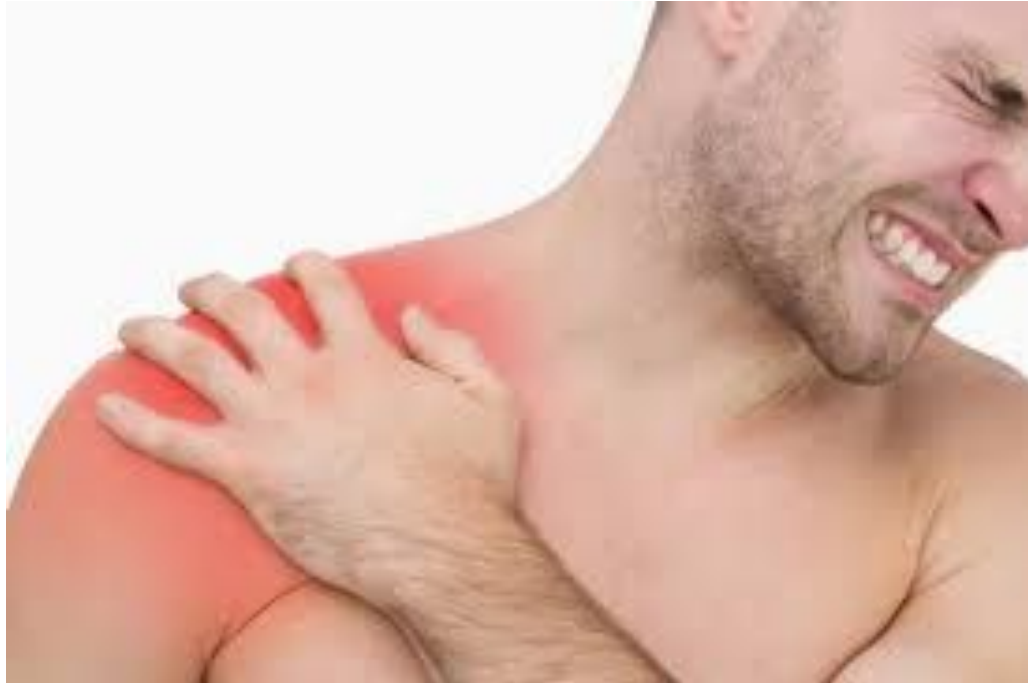



TENDINITIS

Fiona Rattray & Linda Ludwig
Pg.431

TENDINITIS

- ▶ **Tendinitis is inflammation of a tendon.**
- ▶ Tendons are made of regularly arranged, dense collagen fibrils.
- ▶ Tendons attach muscle to bone and are part of the musculotendinous unit.
- ▶ Tendons appear in 2 shapes: Cord like and broad, sheet like called **aponeuroses**.
- ▶ Tendons move in a straight line and they are surrounded by a **paratendon**.
- ▶ A tendon that runs across a bony prominence is surrounded by a **tendon sheath**. Its double-layered tubular structure is filled with synovial fluid. Outer layer is attached to surrounding structures, inner layer surrounds the tendon itself, allowing the tendon to glide through it easily without friction.

TENDINITIS

- ▶ Dense connective tissue of tendons has a limited blood supply originating from muscles and bones.
- ▶ Tendons are subject to great tensile stress.
- ▶ If load is placed on a tendon, waves of its collagen fibres straighten out. They then temporarily deform. 2 actions account for 4% of tendon lengthening. If 4% stretch is not exceeded, the tendon will return to its original length and collagen fibre waves reform. The collagen links begin to fail if the tendon's length is exceeded by 8%.
- ▶ Over time the tendon can experience micro tearing, partial tearing or complete rupture, and blood flow is reduced.

CAUSE & CONTRIBUTING FACTORS

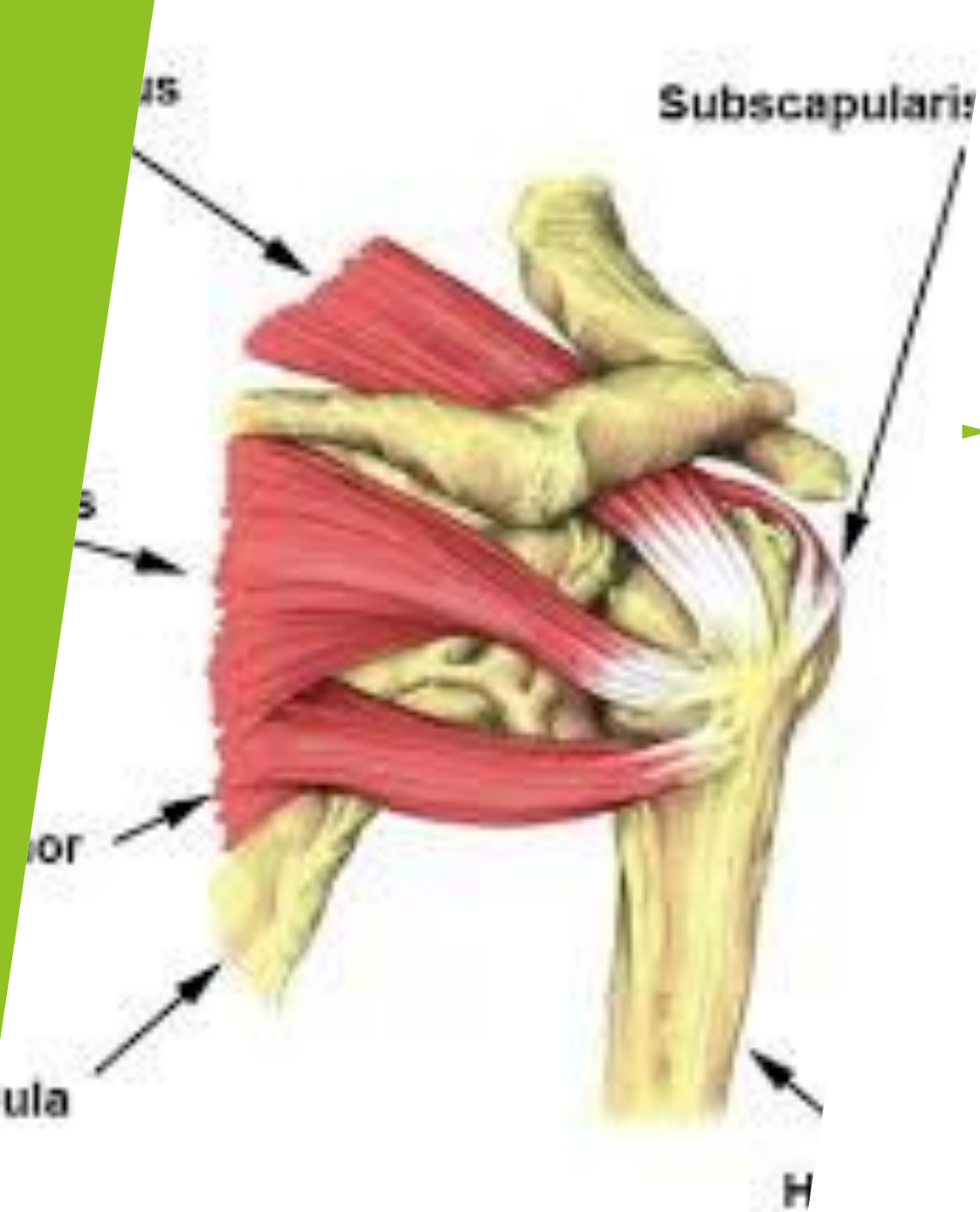- ▶ The **cause** of tendinitis is chronic overload of the tendon, which leads to micro tearing and an inflammatory response.
- ▶ **Contributing factors:** mm imbalances, poor biomechanics, lack of flexibility, chronic degenerative changes, poor blood supply, improper equipment, and training errors.

TYPES OF TENDON OVERUSE INJURIES

- ▶ Tendinitis is classified into four grades of severity:
- ▶ **Grade 1** tendinitis has Pain after activity only.
- ▶ **Grade 2** tendinitis has Pain at the beginning of activity which disappears during activity then returns after activity.
- ▶ **Grade 3** tendinitis has Pain at the beginning of activity, during activity, and after activity. Pain may restrict activity.
- ▶ **Grade 4** tendinitis has Pain with activities of daily living. Pain continues to get worse.

TYPES OF TENDON OVERUSE INJURIES

- ▶ **Paratendinitis** is inflammation of the paratendon or the tendon sheath where these structures are associated with a tendon, either of which may be irritated by the tendon as it rubs over a bony prominence. It is also called Tenosynovitis or Tenovaginitis.
- ▶ **Tenosynovitis** is irritation of the inner surface of the tendon sheath by the roughened surface of the tendon.
- ▶ **Tenovaginitis** is irritation and thickening of the sheath itself.
- ▶ **Tendinosis** are degenerative changes occurring with chronic overuse tendon injuries, like tennis elbow. With tendinosis there are no signs of inflammation in the tendon itself.

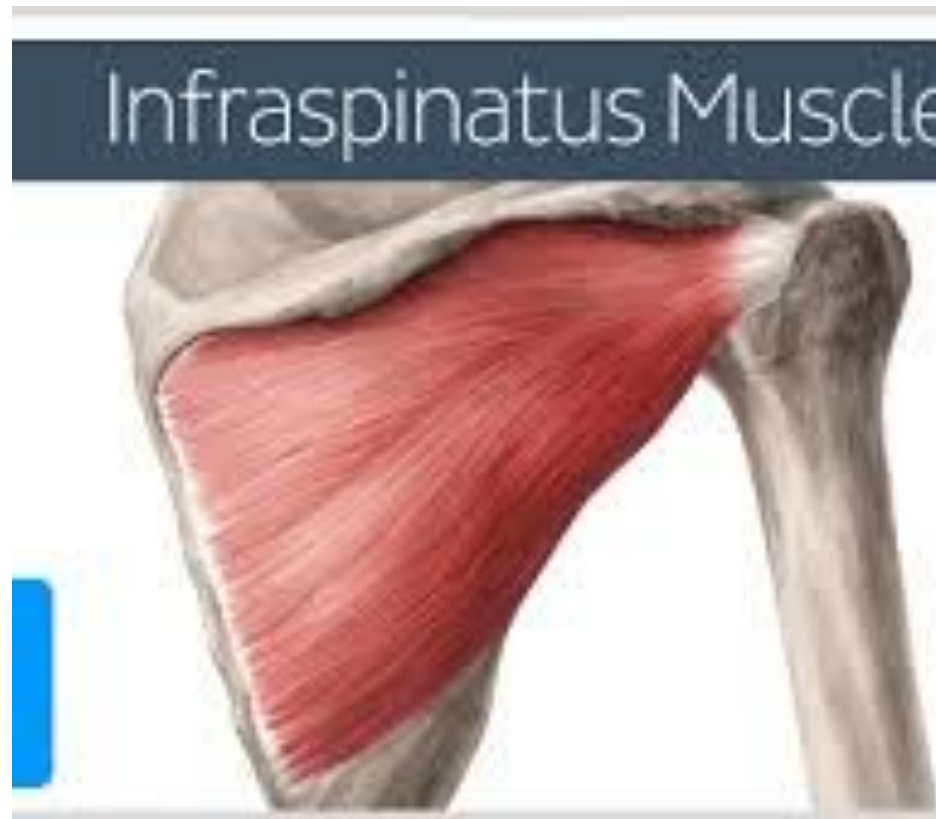

COMMON TENDINITIS LOCATIONS AND CAUSES

- ▶ **Supraspinatus tendon:** To palpate, the arm of the seated client is held behind the back, with the elbow in flexion. The humerus is maximally internally rotated and maximally extended, bringing the humeral head attachment of supraspinatus out from under the acromion. Palpate inferior to the AC joint through deltoid mm between anterior and medial fibres.

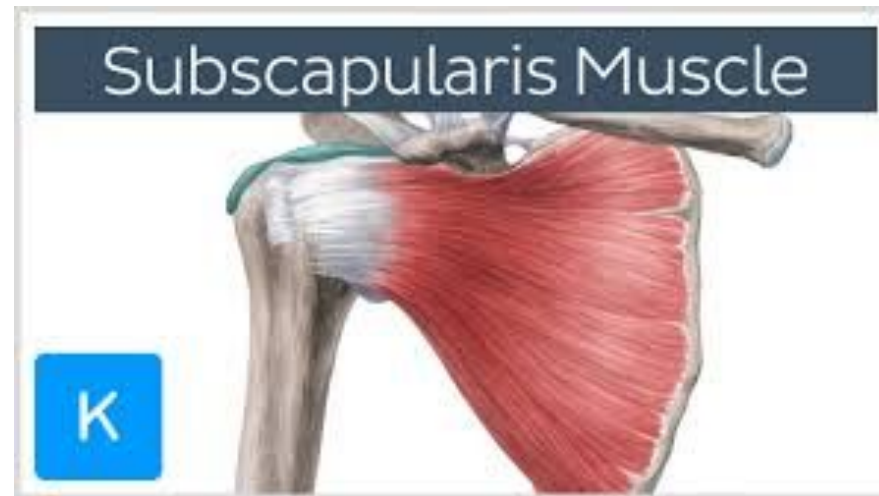INFRASPINATUS TENDON

- ▶ To palpate, the humerus of the seated or prone client is flexed to 90 degrees, adducted 10 degrees and externally rotated 20 degrees. Palpate the tendon inferior to the AC joint and lateral portion of the spine of the scapula. Palpate the tendon through the posterior fibres of the deltoid muscle.



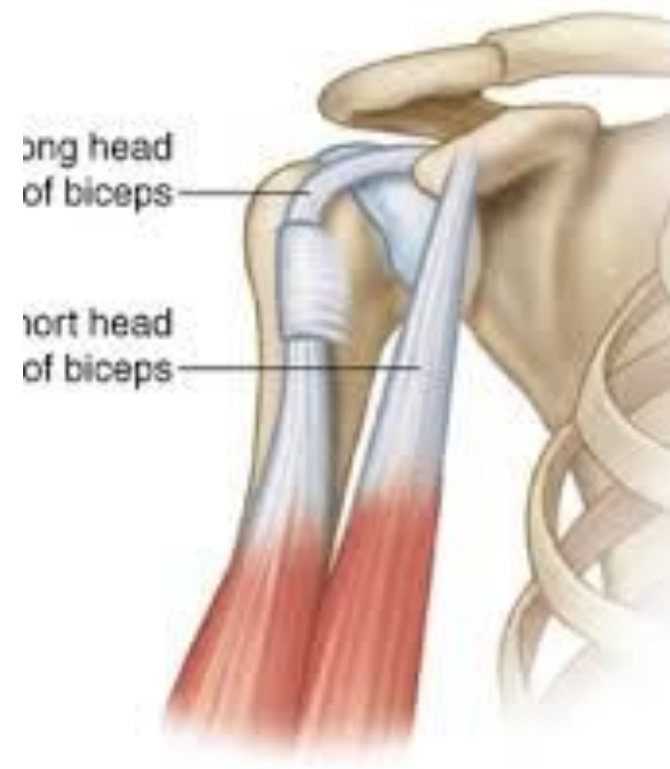
SUBSCAPULARIS TENDON

- ▶ To palpate, the seated client keeps the humerus at the side and the elbow is flexed to 90 degrees. The tendon is palpated inferior to the clavicle, lateral to the coracoid process, medial to the anterior deltoid. The humerus is then medially rotated, returning it to a position midway between external and internal rotation. The tendon is palpated deep in the deltopectoral triangle, between the tendons of the long and short heads of biceps.



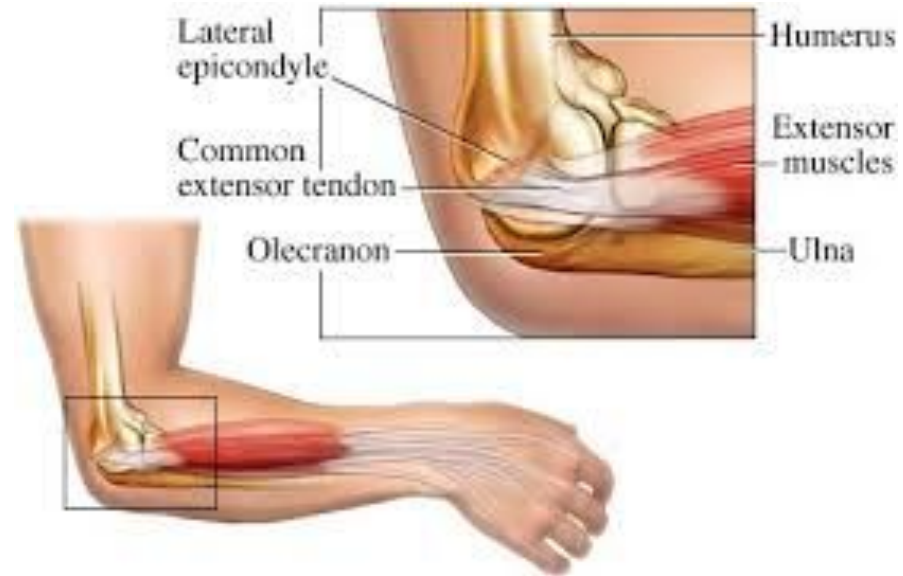BICEPS LONG HEAD TENDON

- ▶ To palpate the long head, the humerus of the seated client is internally rotated 20 degrees or to hands on lap position. The tendon is palpated inferior to the clavicle, lateral to the coracoid process in the same area as the subscapularis tendon. Internally rotating the humerus bring the bicep tendon out from underneath the anterior deltoid mm.



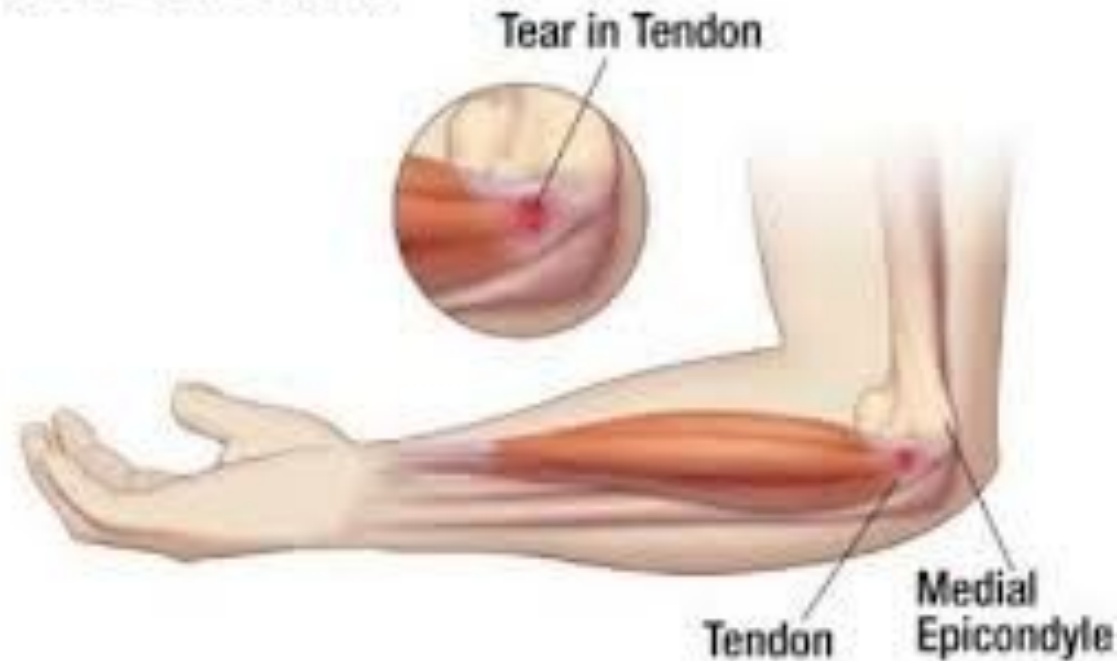COMMON EXTENSOR TENDON

- ▶ To palpate, the elbow of the seated client is placed in slight flexion. The tendon is located distal to the lateral epicondyle. It may extend over the radial head. Pronate and supinate the hand while the therapist palpates the moving head.



COMMON FLEXOR TENDON

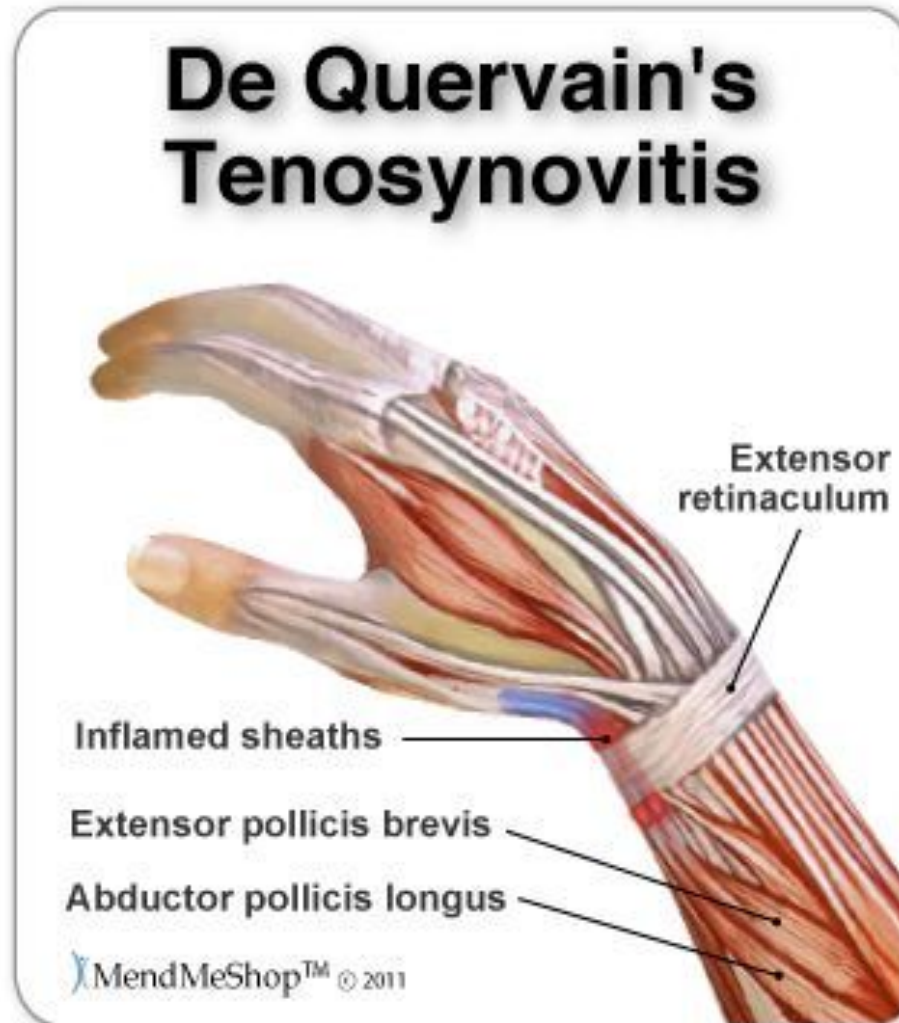
GOITER'S ELBOW
(Medial Epicondylitis)

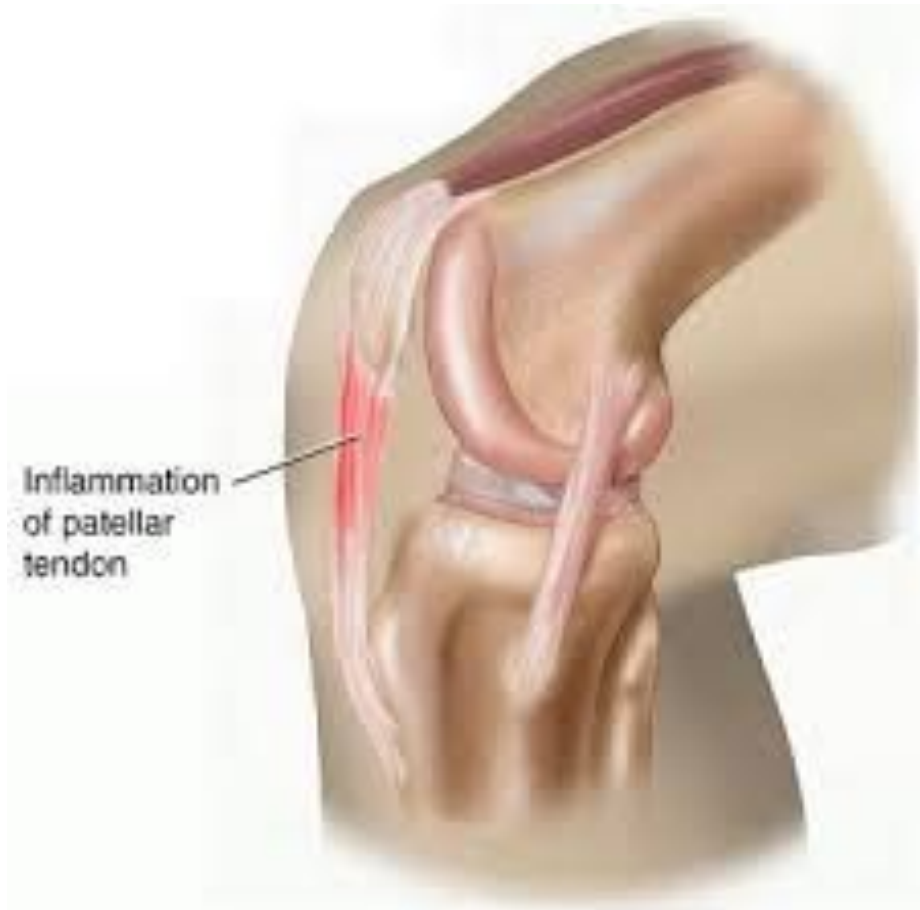

- ▶ To palpate, the elbow of the seated client is placed in flexion and the wrist is supinated. The tendon is located distal to the medial epicondyle.

ABDUCTOR POLLICIS LONGUS & EXTENSOR POLLICIS BREVIS TENDONS

- ▶ Dequervain's tenosynovitis is inflammation of the abductor pollicis longus and extensor pollicis brevis tendon sheaths.
- ▶ The sheaths are palpated at the radial side of the wrist.



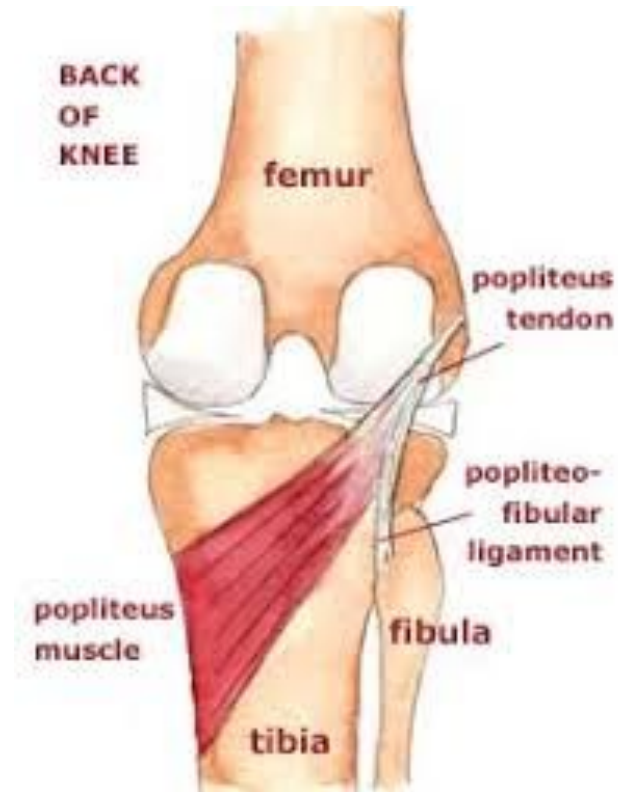


PATELLAR TENDON

The tendon is palpated inferior to the patella.

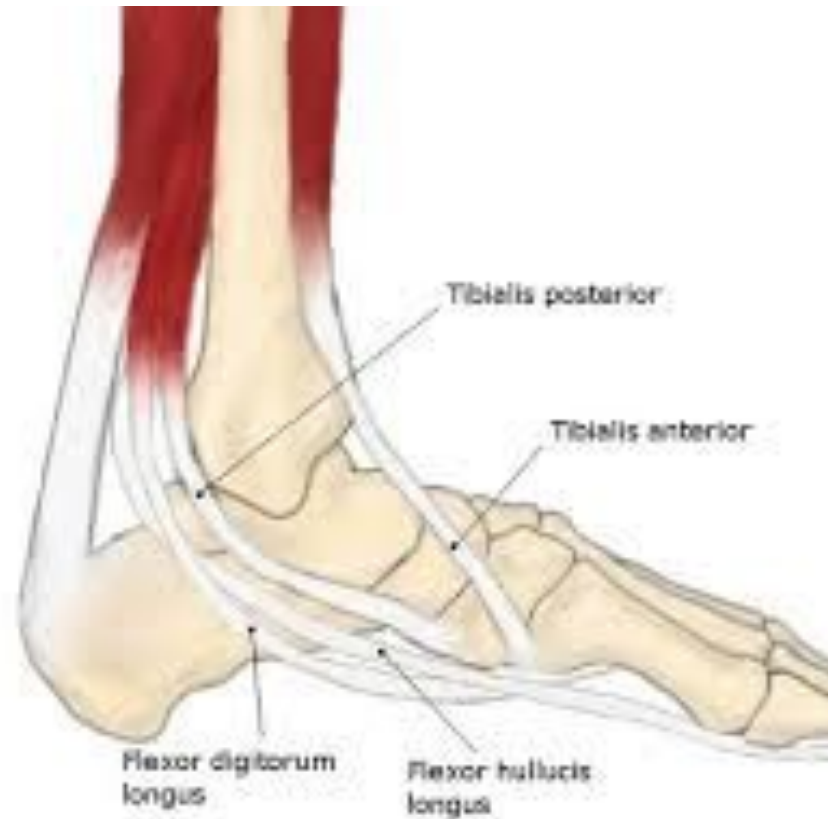POPLITEUS TENDON

- ▶ The tendon is palpated just inferior to the lateral femoral condyle, directly posterior to the lateral collateral ligament and biceps femoris tendon.
- ▶ The tendon is palpated through the lateral gastrocnemius muscle.



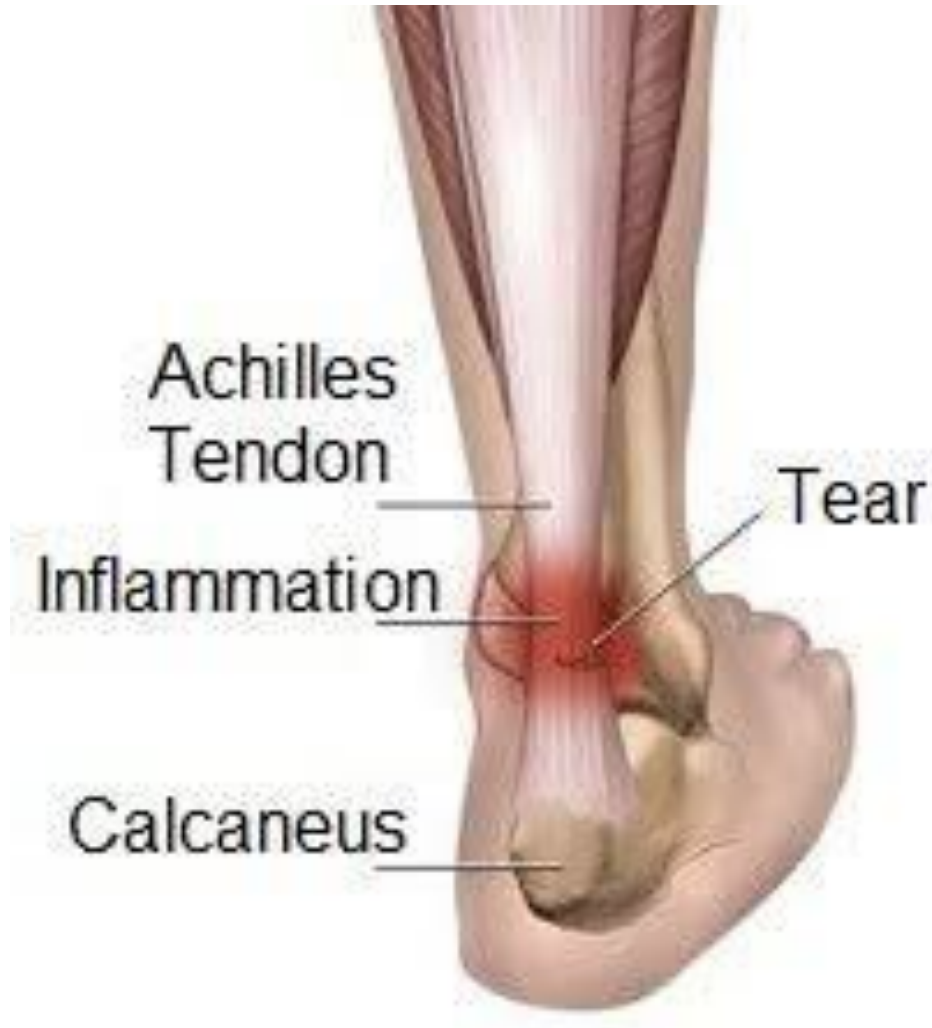TIBIALIS POSTERIOR TENDON

- ▶ To palpate the tendon, the foot is placed in plantarflexion. The tendon in its sheath is palpated just posterior and inferior to the medial malleolus.



ACHILLES TENDON

- ▶ Tendinitis, paratendinitis, and tendinosis can affect the Achilles. This tendon lies between the gastrocnemius-soleus complex and the calcaneus.



MEDICAL TREATMENT OF TENDINITIS & TENDON TEARS

- ▶ Acute tendinitis, inflammation is controlled with rest, ice and NSAID's (non steroidal anti-inflammatory drugs).
- ▶ Stretching, strengthening and gradual return to activity.
- ▶ Steroid injections.
- ▶ Surgical repair with ruptures.
- ▶ Ultrasound

OTHER TENDON PATHOLOGIES

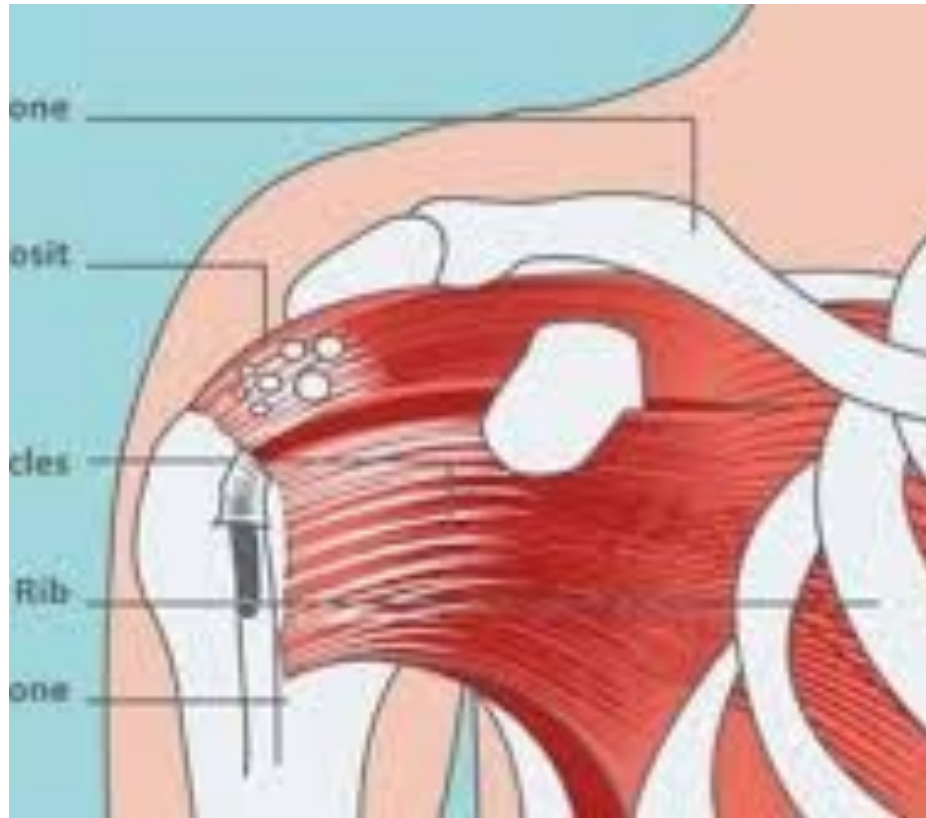
- ▶ **Impingement syndrome, partial or complete tears and calcific tendinitis** are common rotator cuff tendon conditions.
- ▶ **Impingement syndrome** is inflammation, Pain and edema in the tissues within the coracoacromial arch and between the AC and GH joints.
- ▶ Painful compression of the tendons, more so supraspinatus.
- ▶ There are 3 progressive stages of impingement:
- ▶ **Stage 1** there is edema and hemorrhage of the subacromial bursa.
- ▶ **Stage 2** tendinitis and fibrosis are present.
- ▶ **Stage 3** incomplete tears or complete tendinous rupture occurs. There may be bony changes in the acromion and the AC joint. Surgery is indicated.

ROTATOR CUFF TEARS

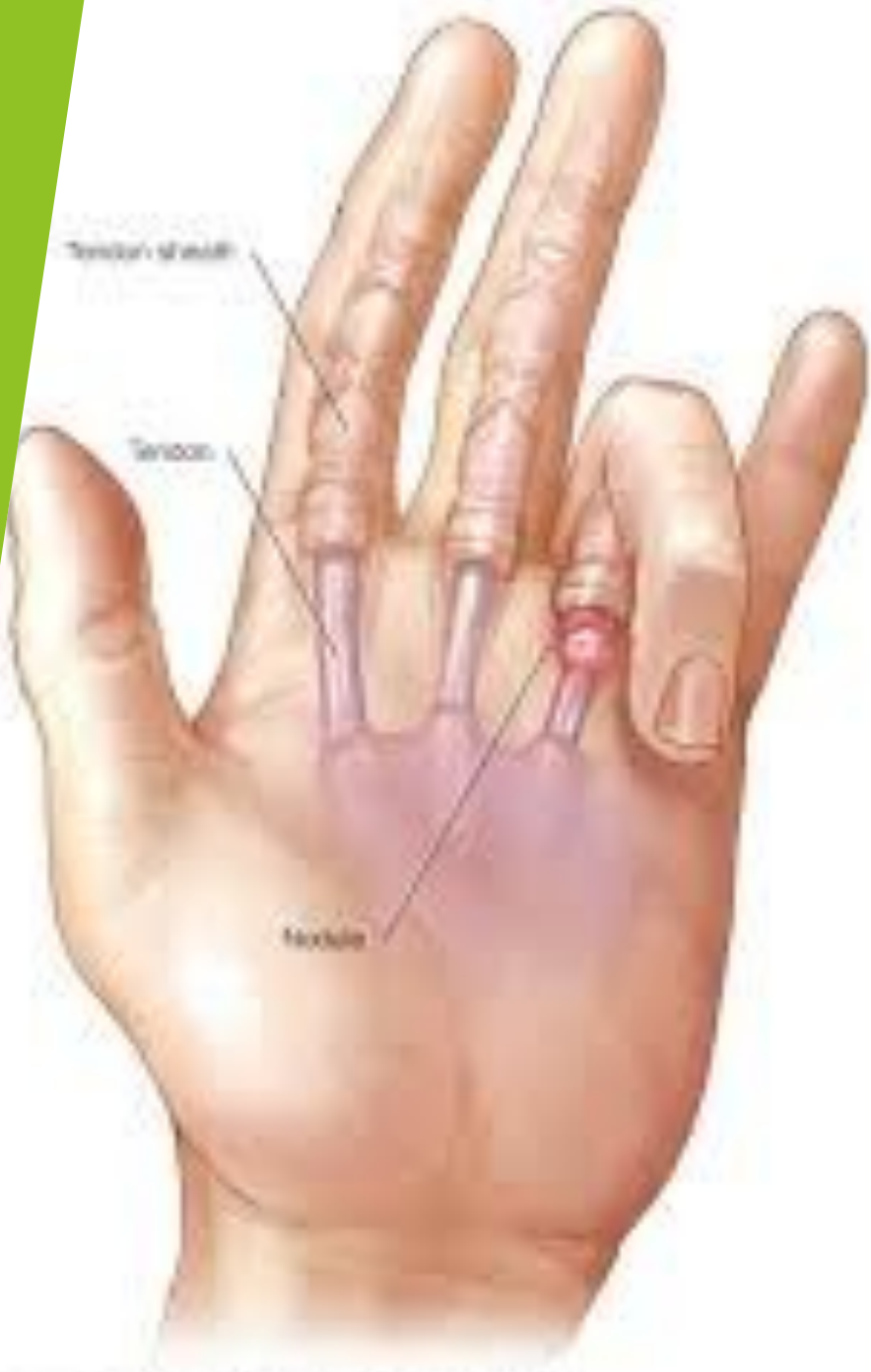- ▶ Overuse, impingement and normal aging can lead to painful tearing of the rotator cuff tendons.
- ▶ Rotator cuff tears may be partial or full thickness, supraspinatus most injured.

CALCIFIC TENDINITIS

- ▶ **Calcific tendinitis** is a late-occurring stage of rotator cuff tendinitis, usually developing in supraspinatus tendon.
- ▶ Supraspinatus functions to hold the head of the humerus in place.
- ▶ The deposits can be soft, toothpaste-like material or hard and chalky.



TRIGGER FINGER



- ▶ Through overuse, flexor tendons of any finger may develop a thickened, nodular swelling.
- ▶ Swelling is unable to move through the tendon sheath and gets caught.
- ▶ The finger is stuck in flexion until it is passively extended by an external force.
- ▶ Rest, NSAIDS, and stretching are common treatments.

REPETITIVE STRAIN INJURY

- ▶ Repetitive movements and poor posture lead to mm fatigue and damage to the muscles, tendons, and nerves of the shoulder's, neck and arms.
- ▶ P, numbness and weakness are present.
- ▶ Risk factors are **intrinsic factors** such as joint hypomobility, lack of exercise, and increased mm tension, poor posture and poor nutrition.
- ▶ **Extrinsic factors:** work environment, task repetition, forced speed or rapid movement and lack of movement of the neck and shoulders.
- ▶ **Psychosocial factors:** Lack of job satisfaction, inadequate co-worker or supervisor support, computer monitoring of task completion, company organizational factors, personal drive to excel and strong work ethic.

SYMPTOM PICTURE

- ▶ Tendinitis is a chronic condition with an initial acute inflammatory stage.
- ▶ Acute: Gradual onset with tenderness local to the tendon, one or two days after activity. P diminishes with renewed activity. Progresses to P during activity as severity increases.
- ▶ Micro tearing occurs with adhesion formation as tendon heals.
- ▶ Inflammation, heat and swelling develop along the tendon or sheath.
- ▶ Crepitus may develop with tenosynovitis and paratendinitis.
- ▶ Decreased ROM

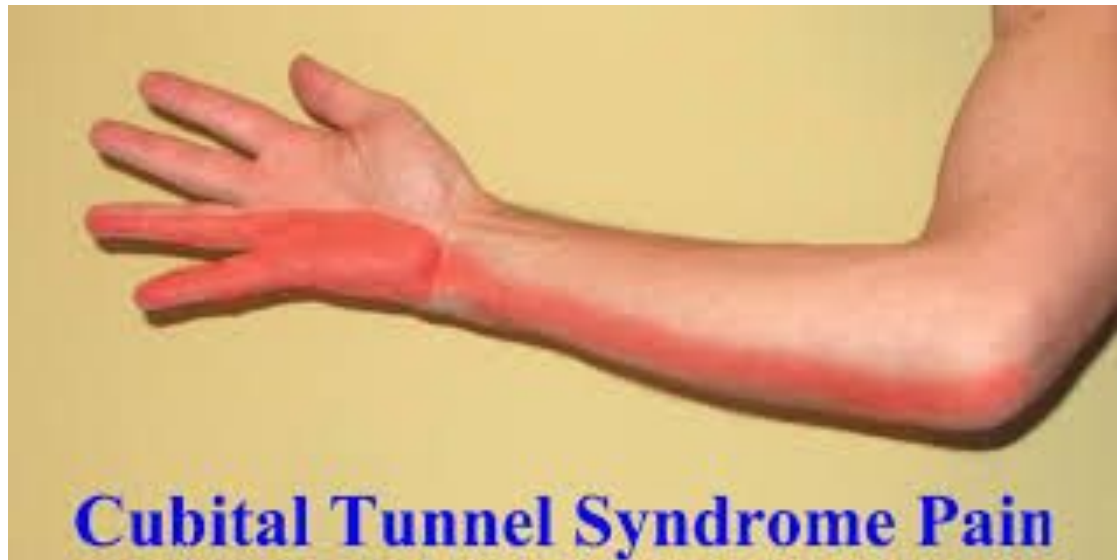CHRONIC

- ▶ P occurs during and after activity.
- ▶ Chronic inflammation, fibrosis, and adhesions.
- ▶ Chronic swelling or thickening.
- ▶ Crepitus.
- ▶ There is decreased ROM and decreased strength.
- ▶ Flare-ups to acute stage.
- ▶ Tendon may degenerate.
- ▶ **Please read observation & palpation, make point form notes of Acute and chronic stages.

TESTING

- ▶ AF ROM of the affected limb is painless.
- ▶ PR ROM may reveal P on actions that fully stretch the affected tendons.
- ▶ AR Isometric testing is painful.
- ▶ **Special Orthopedic tests:** Speed's, Yergason's tests, Mills, Finkelstein's test, reverse Mill's test.
- ▶ Drop arm test, Thompson's test, painful arc and Neer impingement tests.

CUBITAL TUNNEL SYNDROME



- ▶ Is a peripheral nerve compression. The ulnar nerve is entrapped in a fibro-osseous tunnel behind the medial epicondyle or at the flexor carpi ulnaris aponeurosis.
- ▶ Special orthopedic test: **Tinel's sign** may be positive over the ulnar nerve.
- ▶ Paresthesia and P are present at the medial epicondyle and the ulnar side of the hand.

ACUTE TREATMENT

- ▶ **Positioning:** Depends on the location of the tendinitis and the client's comfort.
- ▶ **Hydro:** Cold, Ice pack or a gel pack applied to the affected tendon.
- ▶ Treat compensatory structures, DDB
- ▶ Lymphatic drainage techniques are used on the affected limb.
- ▶ Effleurage, petrissage to proximal limb.
- ▶ TP's are addressed with mm stripping.
- ▶ H+ in the affected mm is treated with GTO on the unaffected tendon of the affected mm.
- ▶ Vibrations are indicated on site.

ACUTE TREATMENT

- ▶ MM squeezing and stroking are used on distal limb.
- ▶ Pain free PR ROM is used on the proximal and affected joints.
- ▶ Gentle joint play applied to hypomobile joints.

CHRONIC TREATMENT

- ▶ **Positioning:** Chosen for comfort and for accessibility of the structures that are treated.
- ▶ **Hydro:** Applications proximal to the tendinitis and on the lesion site itself include **deep moist heat** to soften adhesions.
- ▶ Treat compensatory structures, DDB
- ▶ Fascial glide to assess, then fascial techniques such as crossed-hands and ulnar border spreading, skin rolling over the lesion site.
- ▶ Proximal limb is treated with effleurage, petrissage.
- ▶ Myofascial release through passive lengthening of the mm.
- ▶ Antagonists to the affected mm are treated.

CHRONIC TREATMENT

- ▶ Frictions are applied across the tendon over the tendon adhesions.
- ▶ Stretch for 30 sec or more and ice for up to 5 mins.
- ▶ Distal limb is treated with effleurage and petrissage.
- ▶ Joint Play is used on hypomobile joints.
- ▶ Passive relaxed ROM is used on affected joints.

SELF-CARE ACUTE

- ▶ Rest.
- ▶ Hydro is ice immediately after activity for 5-20 mins.
- ▶ Slow pain free stretch of the affected mm.
- ▶ Regain full strength with a progressive strengthening program.

SELF-CARE CHRONIC

- ▶ Hydrotherapy contrast bath applications, if there are acute flare ups ice is than used.
- ▶ Self massage: mm stripping, and skin rolling.
- ▶ Stretching and strengthening, Isometric than progress to isotonic.

TREATMENT PLAN

- ▶ Start with 3x/week for 2-3 weeks
- ▶ Followed by 2x/week for 1 week, then 1x/week.
- ▶ Client education is key and goal is to get them to a pain free return. The outcome can be based on how long the tendinitis has been present.