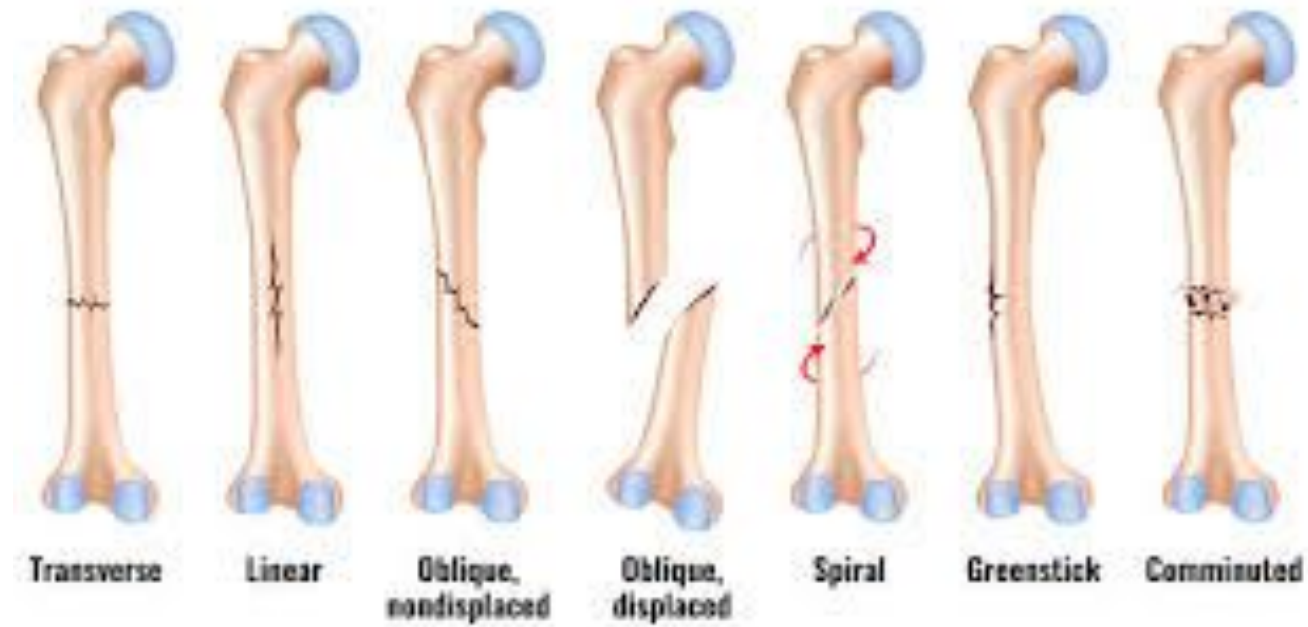



FRACTURES

Fiona Rattray & Linda Ludwig PG.359

FRACTURES

- ▶ **A fracture is a break in the continuity of a bone.**
- ▶ Fractures are classified into several types according to their break, location on the bone and angle.
- ▶ **Closed or simple fracture:** Skin is intact.
- ▶ **Open or compound fracture:** If the ends of the bone have broken through the skin or into one of the body cavities. Open fractures are more prone to infection.
- ▶ **Complete fracture:** Where the bone is broken into 2 or more pieces.
- ▶ **Incomplete fracture:** Where the bone is bent or cracked and the periosteum remains intact.

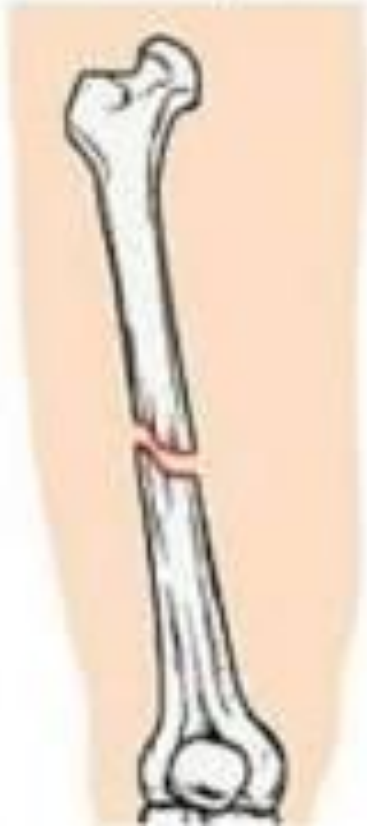FRACTURES

- ▶ Complete fractures are transverse, oblique, spiral, comminuted, avulsion, and osteochondral.
- ▶ Transverse fracture: Usually stay in place after reduction, with tractioning or surgery.
- ▶ Oblique and spiral fracture: More difficult to keep these in place even when splinted, these breaks heal more rapidly.
- ▶ Comminuted fracture: Often unstable, due to it consists of two or more fragments making it difficult to heal.
- ▶ Avulsion fracture: Occurs when a ligament pulls the portion of the bone that it is attached to away from the bone itself.
- ▶ Osteochondral fractures: Occur when fragments of articular cartilage are sheared from the joint surface, usually during dislocation or sprain.

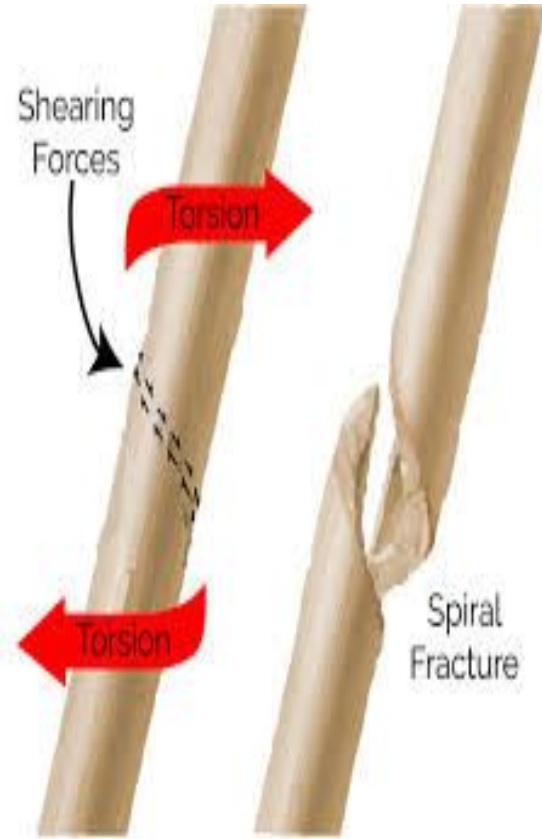
FRACTURES

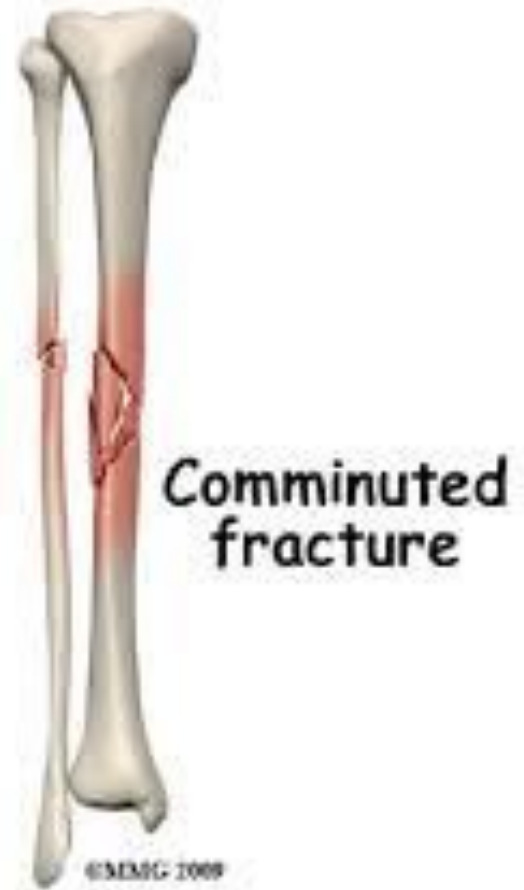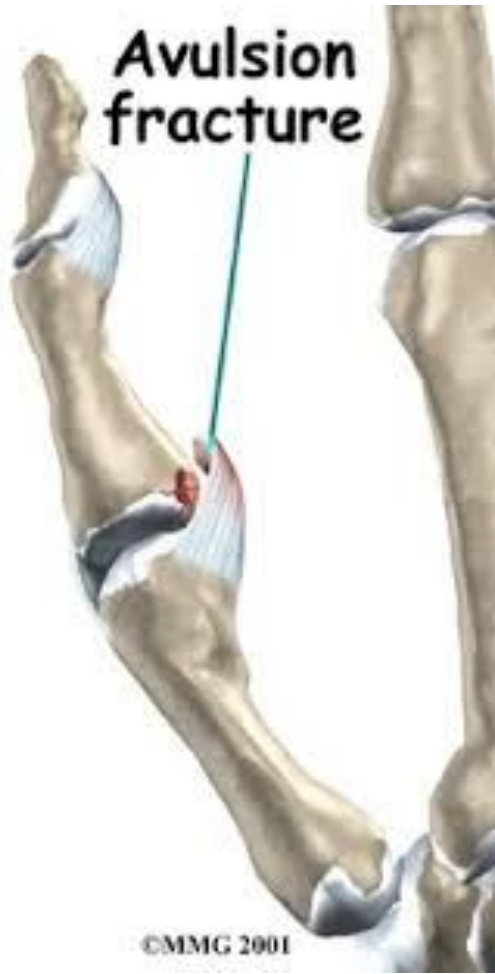- ▶ Incomplete fractures are compression, greenstick, perforation, and stress.
- ▶ Compression fracture: The bone is crushed.
- ▶ Greenstick fracture: The bone is bent or partially broken. These are found in children younger than 10 years of age.
- ▶ Perforation fracture: Are a result of a missile wound, such as a bullet.
- ▶ Stress fracture: Cracks in the bone due to overuse or repetitive actions.

Oblique

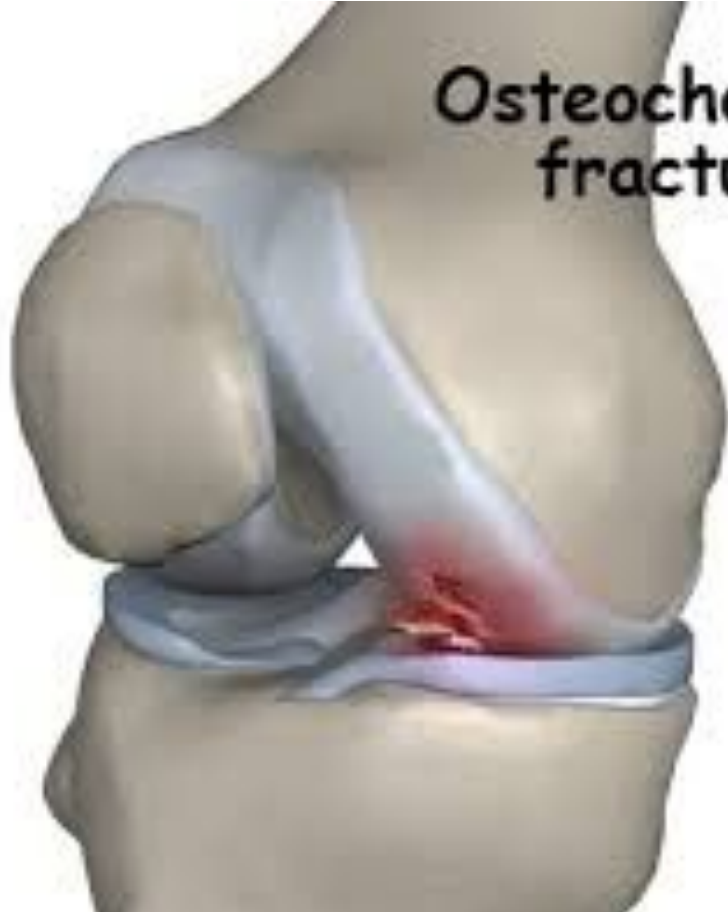

Transverse fracture





**Osteochondral
fracture**



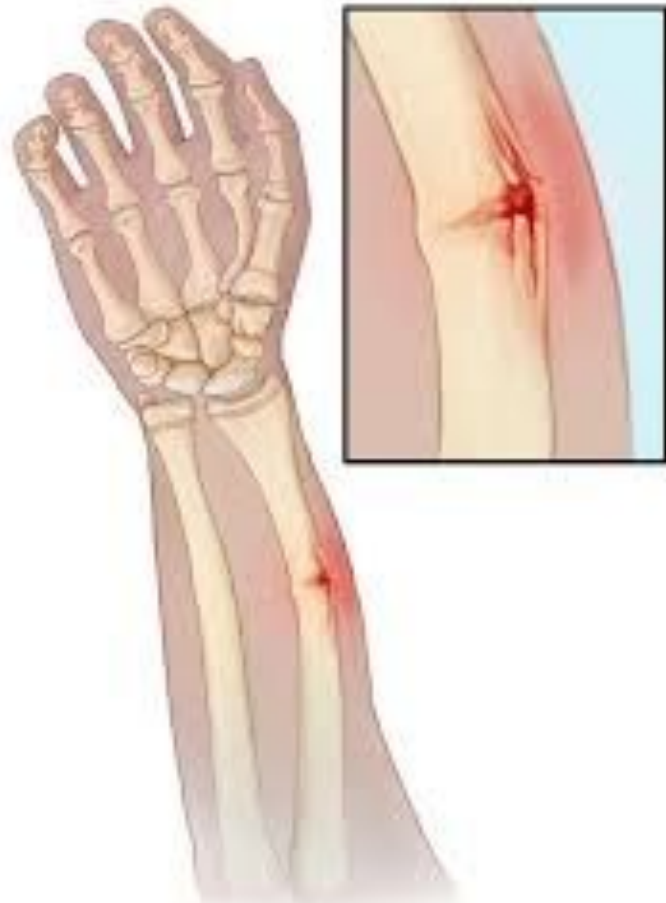
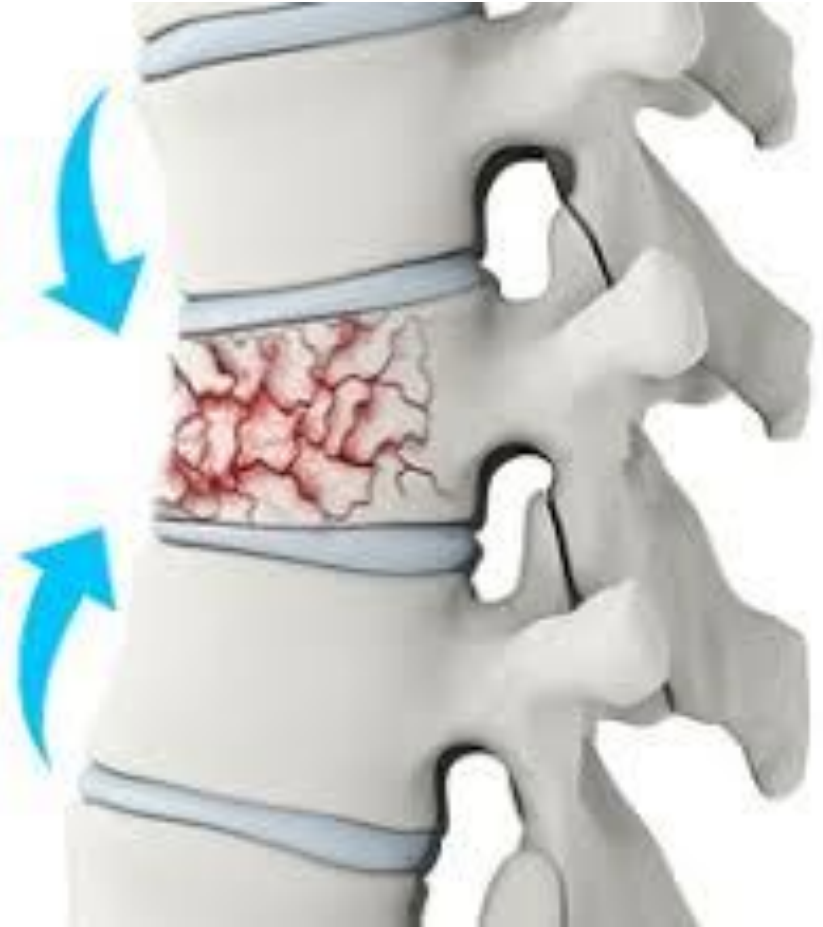
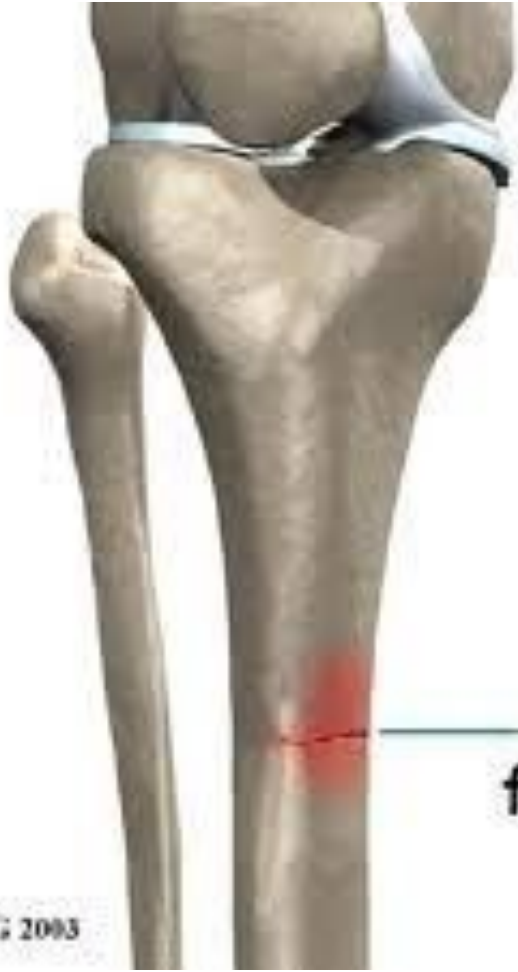FIGURE 10-10 FRACTURE OF THE RADIUS AND ULNA OF THE FOREARM





**Tibial
stress
fracture**

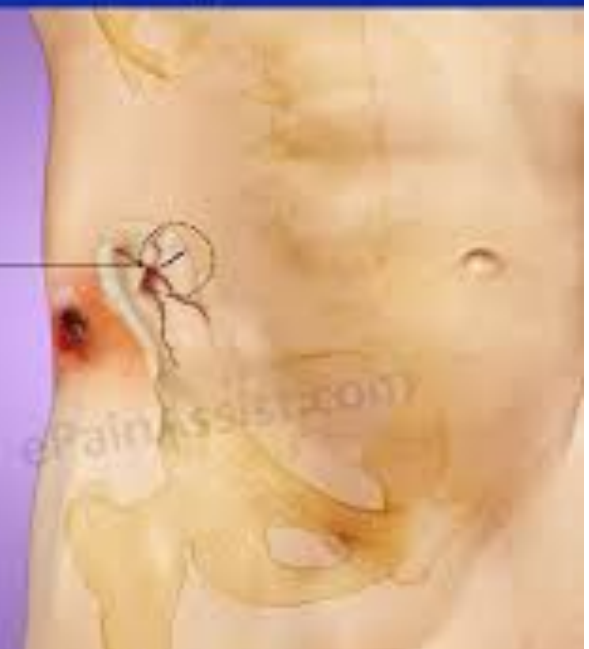©MMG 2003

Gunshot Wound To Hip And Pelvis

Penetrating injuries to the pelvic area may include injury to abdominal and pelvic organs.

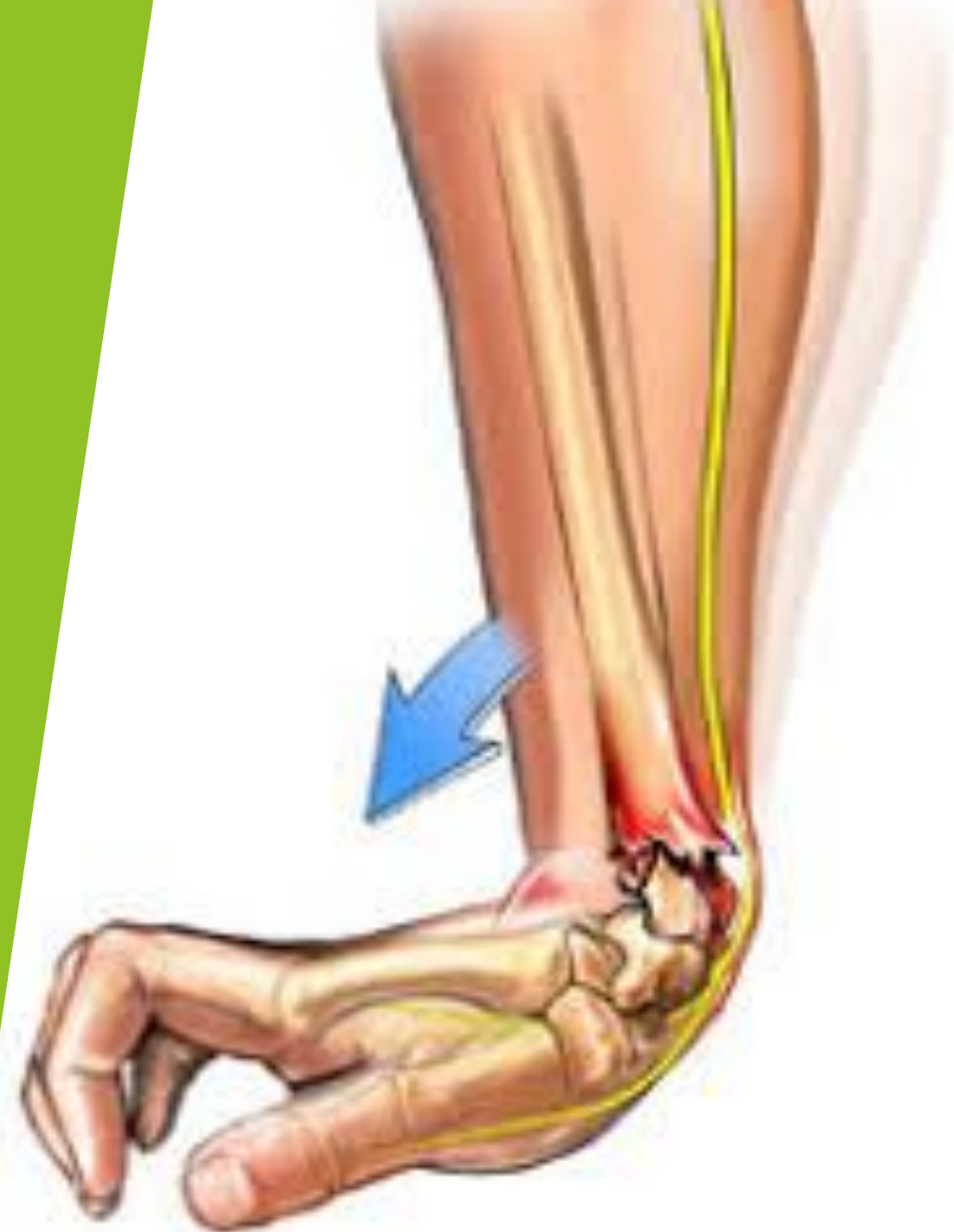Bullet

©2010 ePainAssistant.com



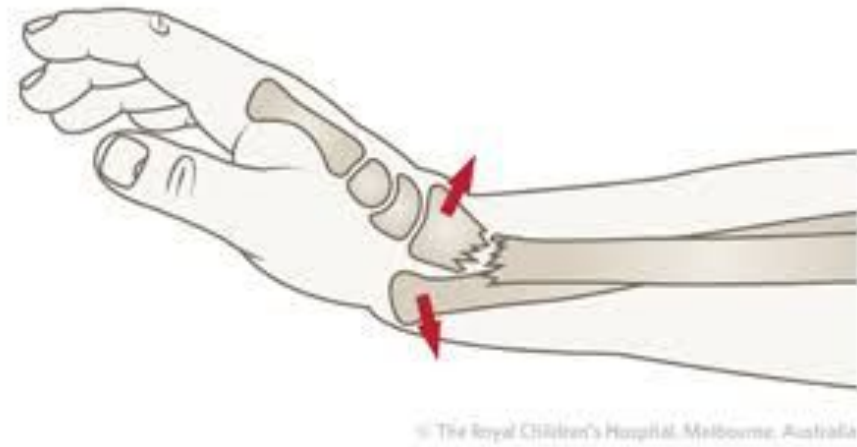COMMON FRACTURE NAMES

- ▶ Colles fracture of the wrist.
- ▶ “Dinner fork” deformity
- ▶ Most common fracture in the elderly.
- ▶ The usual mechanism of injury is a fall onto the outstretched hand.
- ▶ A Colles fracture can be difficult to reduce successfully.
- ▶ The cast is left in place for 4-6 weeks.
- ▶ Complications can be malunion, reflex sympathetic dystrophy, or shoulder-hand syndrome (This is when edema and capsular tightening painfully affect the wrist and shoulder. Carpal tunnel may result).



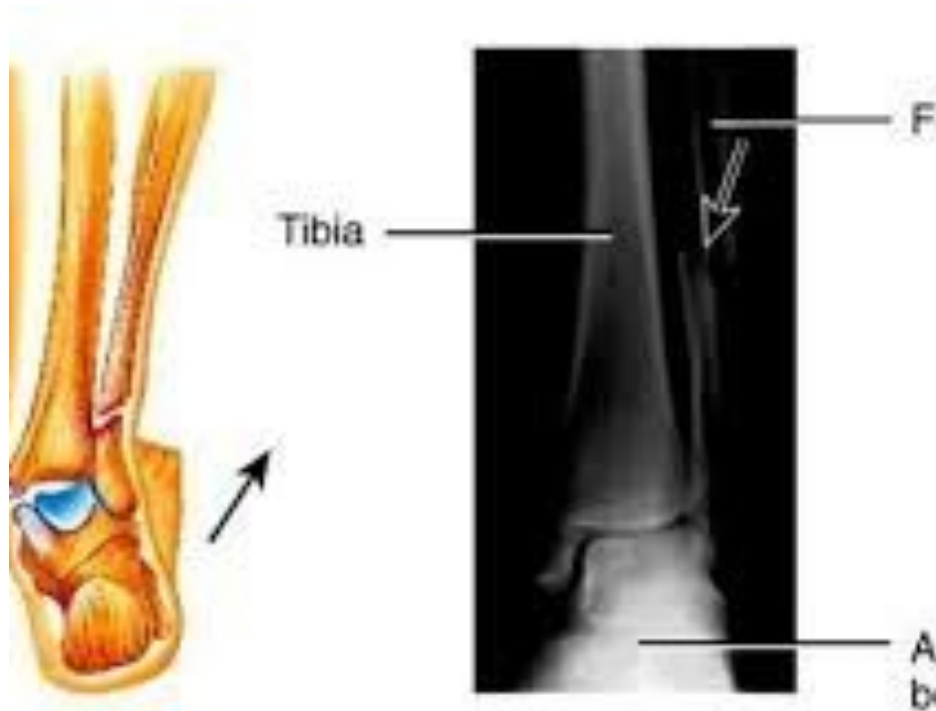GALEAZZI

- ▶ This involves a break of a radial shaft and a dislocation of the inferior radioulnar joint.
- ▶ A fall on the hand with some rotational component is the mechanism of injury.
- ▶ Casting is 6 weeks.
- ▶ An ulnar nerve lesion may occur.



POTT'S FRACTURE

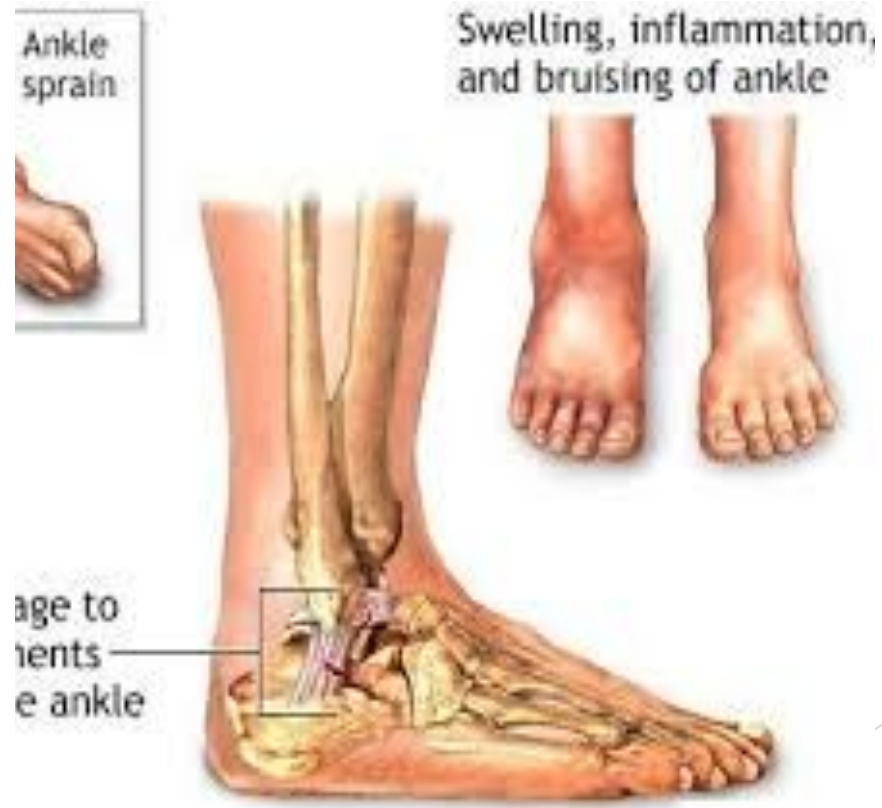- ▶ An ankle fracture that affects one or both malleoli.
- ▶ The distal fibula breaks close to the lateral malleolus.
- ▶ The deltoid ligament may also rupture.



(e) Pott's fracture

DUPUYTRENS FRACTURE

- ▶ The fibula fractures higher up, medial malleoli avulses, and the talus is pushed superiorly between tibia and fibula.
- ▶ Mechanism of injury is usually eversion with some external rotation.
- ▶ Screws or wires are used to stabilize.
- ▶ The leg is casted for 6-12 weeks.
- ▶ Malunion and joint stiffness are some complications.



CAUSES

- ▶ Trauma or sudden force which creates more stress than the bone can absorb.
- ▶ **Direct force**: Object striking it, bone breaks at the point of impact.
- ▶ **Indirect force**: A bone breaks at a distance from the site of force. Example; torquing or twisting proximal and the distal area breaks.
- ▶ Overuse or repeated wear
- ▶ Pathologies: Osteoporosis, tumours, local infection.

STAGES OF HEALING

- ▶ Read Pg.361, in point form write what you will see in each stage, you have 10 mins to complete this.

MEDICAL TX OF FRACTURES

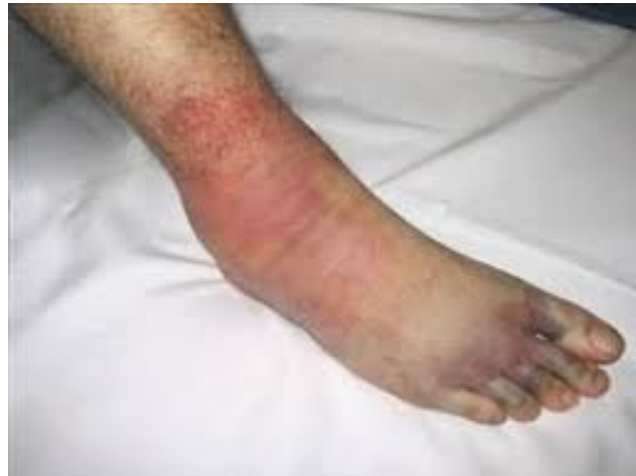- ▶ Closed or open reduction surgery, both of which bring the broken ends into alignment and allow healing to occur.
- ▶ Methods are: Casting, continuous skeletal traction, and external fixation.
- ▶ Closed reduction, manual traction is applied for the bones to realign.
- ▶ Casting or fixation allows the bone ends to unite in a good position.
- ▶ Continuous skeletal traction is used for the femur or tibia. Pins and wires are inserted in this surgery.
- ▶ External fixation devices may be used.
- ▶ In an open reduction, the bones or fragments are stabilized by devices such as screws, nails, wires, long intermedullary nails, and metal plates.

COMPLICATIONS

- ▶ Complications can occur early, or late depending the severity of the fracture.
- ▶ The therapist should look for early signs regarding complications. Make note of any abnormal complications, if any are present refer to medical attention immediately.
- ▶ **Early complications:** Torn muscles, and tendons, ligament damage, compartment syndromes, nerve injuries, vascular injuries, infection, DVT, problems caused by poorly fitting casts.

COMPARTMENT SYNDROME

- ▶ Can occur in the forearm and leg. The swelling accompanies marked edema, hematoma, or inflammation increases in the fascial compartment.
- ▶ Leads to reduced circulation, ischemia of the mm's within the compartment, than more edema, followed by increased pressure and more intense ischemia.



EARLY COMPLICATIONS

- ▶ **Nerve compression:** May be indicated by paresthesia in the tissues under the cast.
- ▶ **Bone and soft tissue infections:** External and skeletal traction along the pin tract if the wound is not properly cared for.
- ▶ **Deep vein thrombosis:** May occur after a lower limb fracture, more so seen in the gastroc mm.
- ▶ **Pressure or plaster sore:** Occurs where the cast ischemically compresses the skin over a boney prominence.
- ▶ **Cast dermatitis:** May result from poor ventilation and hygiene of the skin under the cast.
- ▶ **Loose cast syndrome:** Occurs when a cast is too loose and rubs on bony prominences, causing abrasions.

LATE COMPLICATIONS

- ▶ Include delayed union and non-union, malunion, myositis ossificans, nerve compression, nerve entrapments, bone necrosis, joint stiffness, and disuse atrophy.
- ▶ **Delayed union:** Occurs if the bone does not unite within the expected time frame. Possible factors are inadequate circulation, insufficient splinting, excessive traction or infection.
- ▶ **Non-union:** Failure of the bone to heal before the repair process finishes. Possible factors can be caused by an overly large gap between the bone ends either due to bone destruction, bone loss, excessive tractioning, infection.
- ▶ **Malunion:** Unacceptable joining of the bone ends, deformity then occurs. This may be due to improper alignment of the bone ends when the fracture is reduced or displaced.

LATE COMPLICATIONS

- ▶ **Myositis ossificans:** Bone formation within a mm, occurs weeks after the initial trauma, such as fracture, or dislocation, or potential mm injury.
- ▶ **Avascular bone necrosis:** Occurs in an area of bone that is poorly vascularized.
- ▶ **Disuse osteoporosis:** May occur with prolonged immobilization.
- ▶ **Metal plates:** Local inflammation may be due to metallic ions releasing.
- ▶ **Plates and screws:** May loosen or break if the limb is not properly casted until the bone heals and a load is placed on the limb.

SYMPTOM PICTURE

- ▶ Prior to reduction, mobility and deformity, the client will experience, shock, P, bleeding, inflammation, swelling, loss of function, muscle splinting, and edema.
- ▶ The soft tissue may also be injured, such as periosteum, ligaments, tendons, nerve, blood vessels, muscle, fascia and skin.
- ▶ Stress fractures, fracture is painful upon compression.

DURING MOBILIZATION

- ▶ Post closed or open reduction, the limb may be casted.
- ▶ Open reduction that has not been casted or externally fixed, incisions or pins are possible sites of infections. Crutches, taping, and other supports may be present.
- ▶ P is present both locally and potentially distant.
- ▶ Tissue repair and callus formation, adhesions are developing.
- ▶ Immobilization can reduce circulation, edema, disuse atrophy, and Connective Tissue contracture, under the cast.
- ▶ H⁺ and TP's are present in compensatory structures.
- ▶ Short term complications, such as compartment syndrome, nerve compression, infection, plaster sores, poor cast fit or non-union.

IMMOBILIZATION REMOVED

- ▶ Fracture site is healing and remodeling.
- ▶ Decreased tissue health that has been under the cast. For the first few days post immobilization, the tissue is somewhat fragile, and mm tone is decreased.
- ▶ Adhesions have matured, CT contractures, P and stiffness may be present. There may also be loss of proprioception.
- ▶ Open reduction, scars may be present.
- ▶ H+ and TP's may be present, altered posture and gait possible.
- ▶ Mm weakness and disuse atrophy are present.
- ▶ Occasionally, chronic edema may be present.
- ▶ Long term complications such as delayed union, non-union, malunion, myositis ossificans, nerve compression.

OBSERVATIONS

- ▶ ****Read Health History questions Pg.367**
- ▶ ****Please read observations & palpation on Pg.368-369**

TESTING DURING IMMOBILIZATION

- ▶ Testing of mm's and jts involved are CI'd.
- ▶ AF ROM of the proximal and distal jts within pain free ranges.

TESTING

IMMOBILIZATION REMOVED

- ▶ **AF ROM** of the proximal and distal jts may be carefully performed. AF ROM are reduced.
- ▶ **PR ROM** performed with care. Careful pain-free passive relaxed ROM reveals ranges with a tissue-stretch end feel.
- ▶ Overpressure is CI'd.
- ▶ **AR strength testing** is performed sub maximally and increasing gradually to maximum pain-free contraction.

REDUCTION WITH NO CASTING

- ▶ A fracture that has been surgically reduced either by external fixation by pins or plates, and where no casting is present. Testing follows immobilization removed.
- ▶ Disuse atrophy is less likely to occur.
- ▶ Even though bones are fixed by implants, bony consolidation has to occur before over pressure is applied.

SPECIAL TESTS

- ▶ Compartment syndrome in the leg or forearm, Passive hyperextension test of the fingers or toes will result in P.

CONTRAINDICATIONS

- ▶ **During immobilization:** The limb must not be tractioned before union.
- ▶ Hot hydro should not be placed distal or immediately proximal to the cast.
- ▶ AF and AR isometrics should not be performed prior to physicians approval.
- ▶ Open reduction: on site work is avoided until the skin has healed.
- ▶ Open reduction and stabilized without a cast, infection is possible. Local techniques are avoided until the skin is fully healed.
- ▶ **Immobilization Removed:** Over pressure testing of the involved jts is CI'd before union has occurred.
- ▶ Hydro temperature extremes are avoided on the tissues that were under the cast.

CONTRAINDICATIONS

- ▶ The client may experience dysesthesia* (It is defined as an unpleasant, abnormal sense of touch. It often presents as pain but may also present as an inappropriate, but not discomforting, sensation) in the limb when the cast first comes off.
- ▶ The clients perception of heat, cold, and pressure may be altered.
- ▶ Until tissue health and mm tone are regained in the mm's that were under the cast, its CI'd to use deep longitudinal techniques on these mm's. Passive stretching should be done carefully and to the onset of P only to avoid further trauma.
- ▶ If metal implants such as pins, or plates have been used to repair the fracture, avoid local hot hydro.

TREATMENT DURING IMMOBILIZATION

- ▶ **Positioning:** Depends on the location of the fracture and the clients comfort. The limb is elevated and secured so no stress is placed on the fracture site.
- ▶ **Hydro:** Cold application applied to the limb distal to the cast, hydro to compensatory structures include heat and or contrast, but not applied immediately proximal to the cast.
- ▶ Treat compensatory structures, DDB.
- ▶ Lymphatic drainage to proximal area of the cast.
- ▶ Proximal unidirectional effleurage, petrissage.
- ▶ Before union occurs, no tractioning indicated.
- ▶ Mid-range pain free passive relaxed ROM to proximal and distal jts.

TREATMENT DURING IMMOBILIZATION

- ▶ Vibrations through the cast.
- ▶ Work distal to the cast is restricted to light stroking, mm squeezing, and vibrations.

TREATMENT IMMOBILIZATION REMOVED

- ▶ **Positioning**: Chosen for comfort and for accessibility to the structures.
- ▶ **If you are treating the client in the days immediately post removal of the cast before soft tissue health has returned, hydro modifications need to be observed.
- ▶ **Mild contrast hydro** is initially used on the tissues that were under the cast.
- ▶ Once mm tone has returned, **Deep moist heat** is indicated. Reminder not to apply heat directly over any metal implants.
- ▶ Treat compensatory structures, DDB
- ▶ Proximal lymphatic drainage if edema is present.
- ▶ Proximal effleurage, petrissage, ischemic compressions.

TREATMENT

IMMOBILIZATION REMOVED

- ▶ Stimulating, light techniques on the mm's suffering disuse atrophy.
- ▶ Gentle petrissage is indicated.
- ▶ Pain free mid range passive relaxed and active assisted ROM are interspersed.
- ▶ Joint play are indicated at hypomobile jts.
- ▶ As tissue health improves and mm tone returns, on site focus is reducing adhesions and scar tissue.
- ▶ Fascial techniques are used to treat proximal restrictions.
- ▶ Distal limb is treated with effleurage and petrissage.

SELF-CARE

- ▶ During immobilization: The limb is elevated as often as possible.
- ▶ Educate your client to be alert for signs of early complications such as increased P, heat, and swelling. Refer to physician if these signs are present.
- ▶ Hydro is chosen based on healing stage.
- ▶ Remedial exercise is developed for two areas, compensatory structures and mm's under the cast.
- ▶ When exercise is permitted, strength and flexibility should be maintained in the compensatory structures.
- ▶ Strengthening is indicated as per physicians orders, sub maximal isometric contractions of the mm's under the cast are performed.

SELF-CARE

- ▶ **Immobilization Removed:** The limb should be elevated as often if any edema remains.
- ▶ Hydrotherapy when the cast is first removed are cool or mild contrast on site.
- ▶ Remedial exercise is continued for the compensatory structures.
- ▶ AFROM for jts that were under the cast is performed to the onset of P only.
- ▶ Stretches are indicated to regain ROM once consolidation has occurred.
- ▶ If proprioception is reduced at joints, proprioception exercises are indicated.
- ▶ Self massage to adhesions is indicated.

TREATMENT FREQUENCY AND EXPECTED OUTCOME

- ▶ 1-2X/WEEK, until the cast is removed.
- ▶ 2x/week for shorter treatments when the cast is first removed.
- ▶ Upper limb fractures usually heal more quickly.
- ▶ Stress fractures take 6-10 weeks to heal completely.
- ▶ See the suggested healing times shown in the table on PG.377