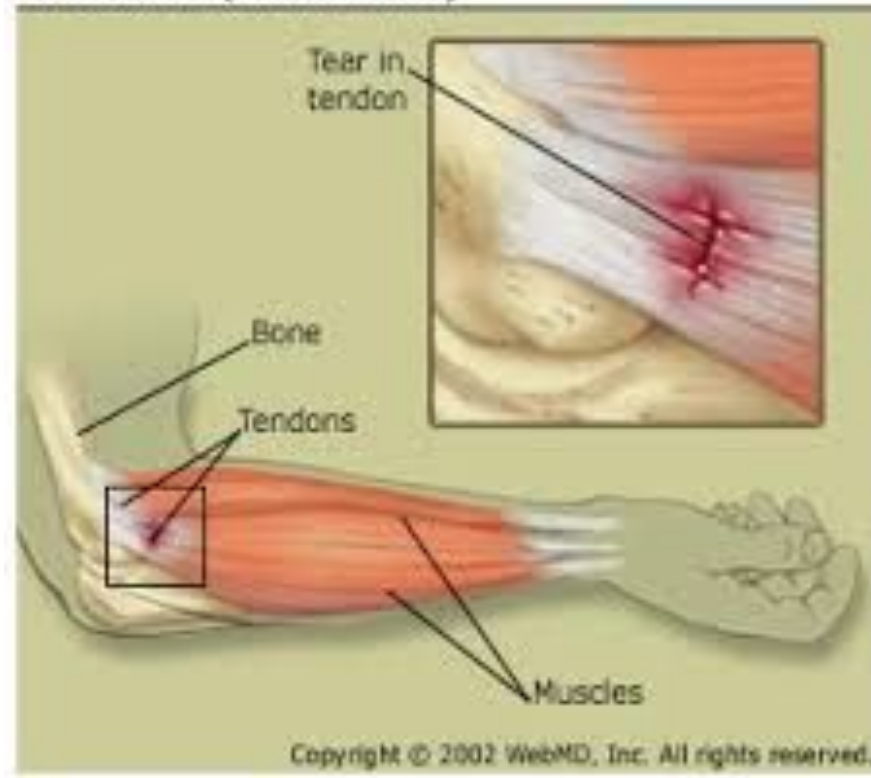


Tendinitis (Elbow strain)



STRAINS

Fiona Rattray & Linda
Ludwig Pg.285

A dark grey arrow points to the right from the left edge of the slide. Below it, several thin, curved lines in shades of blue and grey sweep across the left side of the slide.

STRAINS

- **A strain is an overstretch injury to a musculotendinous unit.**
- A musculotendinous unit is the muscle, its tendon's, their osseous attachments and the musculotendinous junction.
- There are 2 types of mm contraction: **Concentric and eccentric**
- **Concentric:** Muscle contraction, the origin and insertion of the mm come closer together, the mm fibres shorten.
- **Eccentric:** Muscle contraction, as the origin and insertion move farther apart, the mm fibres lengthen.
- Tendons are moderately vascularized. They are prone to partial or complete rupture at the area of least blood supply. Usually either in the middle of the tendon, or at the musculotendinous junction.



CAUSES

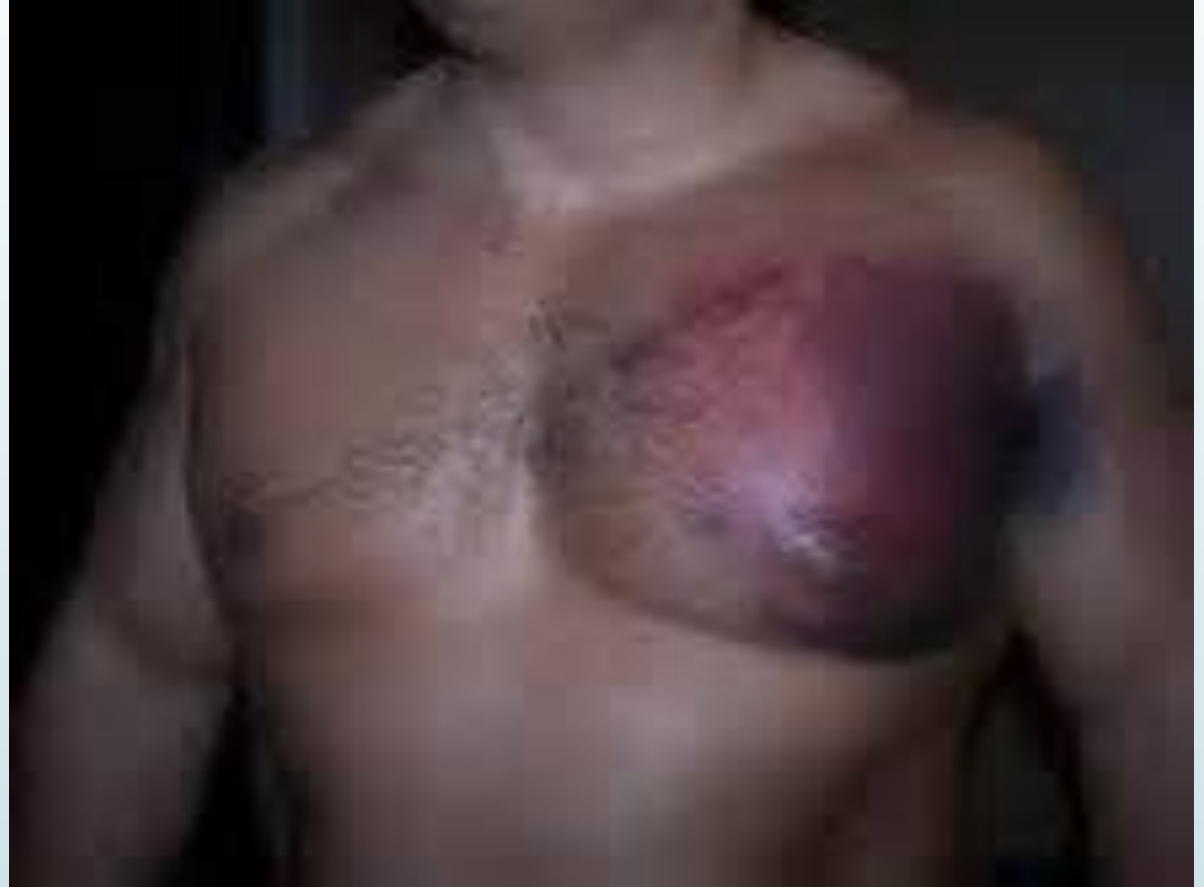- A sudden overstretching of the mm.
- An extreme contraction of the mm against heavy resistance.
- Strains are classified according to 3 levels of severity.
- **Grade 1, Mild or First degree strain:** Minor stretch, and tear to the musculotendinous unit. Minimal loss of strength, the person can continue the activity with mild discomfort.
- **Grade 2, Moderate or second degree strain:** Tearing of the musculotendinous fibres. The tear is variable, moderate to severe. There may be a snapping sensation or sound at the time of injury. Palpable gap may be present. The person may have difficulty continuing the activity.

A dark grey arrow points to the right from the left edge of the slide. Below it, several thin, curved lines in shades of blue and grey sweep across the left side of the slide.

CAUSES

- **Grade 3, Severe or Third degree strain:** This is a complete rupture of the musculotendinous unit or avulsion fracture, the bony attachments of the tendon is torn off while the unit remains intact. There is a snapping sensation or sound at the time of rupture. Palpable gap is visible at the injury site. Often, the mm shortens and bunches up. The person cannot continue the activity due to significant P and mm weakness.
- In the acute stage the client should be referred to their physician.
- MM's and tendons in acute stage Grade 3 will be surgically repaired.
- Grade 1 or 2 strain, after acute stage has passed, ROM and strengthening are most crucial to maintain and increase.

Grade 3 Muscle Strain



A dark grey arrow points to the right from the left edge of the slide. Below it, several thin, curved lines in shades of blue and grey sweep across the left side of the slide.

SYMPTOM PICTURE ACUTE

- **Grade 1:** Minor stretch to the musculotendinous unit, minor discomfort locally, local edema, heat, bruising.
- Tenderness at the lesion site.
- Little to no loss of strength and ROM.
- The client can continue ADL's.
- **Grade 2:** Tearing of several or many fibres of the musculotendinous unit.
- Snapping noise or sensation at the time of the injury.
- Moderate local edema, heat, hematoma, and bruising.
- A gap may be palpable.
- Moderate tenderness and moderate P with contraction of the mm.



SYMPTOM PICTURE ACUTE

- There is moderate loss of strength and ROM.
- The client has difficulty continuing ADL's, and experiences disability the next day.
- **Grade 3:** Complete rupture of the mm, or an avulsion fracture of the tendinous attachment.
- Snapping noise, or sensation at the time of the injury.
- Local edema, heat, hematoma and bruising.
- A gap is palpable, and the mm is likely bunched up due to spasmodic contractions.
- Severe P and immediate loss of strength and ROM.
- The client cannot continue ADL's.

A dark grey arrow points to the right at the top left. Below it, several thin, curved lines in shades of blue and grey sweep across the left side of the slide.

EARLY SUB-ACUTE

- **Grade 1:** Little to no P and reduced strength.
- **Grade 2:** P and moderately reduced strength.
- **Grade 3:** P and reduced strength, bruising is black and blue and a hematoma is present. Alteration in the contour of the mm. Potential gap in the tissue and the mm may bunch up.
- P, edema, and inflammation.
- Adhesions are developing around the site.
- Tendons are hypo vascular, they heal slow.
- Protective mm spasms, TP's in the affected mm, synergists, and antagonists.
- **Grade 2&3:** The mm is still bandaged or casted, ROM is reduced.

A dark grey arrow points to the right from the left edge of the slide. Below it, several thin, curved lines in shades of blue and grey sweep across the left side of the slide.

LATE SUB-ACUTE

- **Grade 2&3:** Bruising is yellow, green, and brown. Hematoma has diminished, and gap is still palpable.
- P, edema, and inflammation are decreasing.
- Protective mm spasm is replaced with increased mm tone, TP's are developing in compensatory mm's.
- Adhesions are maturing around the injury.
- ROM is reduced.

CHRONIC

- Bruising is gone, H+ and TP's are present in the affected mm and compensatory structures.
- Adhesions have matured around the injury.
- Tissue may be cool due to ischemia.
- Discomfort local to the lesion site if the mm is stretched.
- **Grade 2&3:** Full ROM reduced.
- **Grade 3:** If surgery is performed, casting may present.
- There is reduced strength of the affected mm and possible disuse atrophy.
- **** Please read observations, and palpation, make point form notes in each stage.**

TESTING

- **Acute:** AF ROM will be reduced. Grade 1 strain mild local P when the mm is contracted, ROM is near normal. Grade 2, the P is moderate and mild ROM is possible. Grade 3, P is moderate to severe and there is loss of function.
- **Grade 2 and 3:** All other testing is CI'd.
- **PR ROM:** Grade 1, testing the painful range last. Potential for a muscle spasm end feel when the mm reaches it's end range. P is also encountered with mm approximation.
- **AR Isometric testing:** Grade 1, reveals minor loss of strength and discomfort.



TESTING EARLY & LATE SUB ACUTE

- **AF ROM** is reduced. The ROM is limited due to P, but less than in the acute stage.
- **PR ROM:** Testing the most painful range last. A painful tissue stretch end range is felt. P may be present with tissue approximation.
- **AR Isometric testing:** P is experienced at the injury site. AR strength tests are weak with a strain of the following mm's: tibialis posterior, tibialis anterior, peroneal's, gluteus maximus, glute med, piriformis, iliopsoas, rhomboids, mid traps, anterior neck flexors.



TESTING CHRONIC

- **AF ROM:** of the affected mm may be limited due to P, at end ranges of motion.
- **PR ROM:** Testing the most painful range last, tissue stretch end feel on a fully stretched mm.
- **AR Isometric testing:** may reveal decreased mm strength, more with disuse atrophy or grade 3 strains.

A dark grey arrow points to the right from the left edge of the slide. Below it, several thin, curved lines in shades of blue and grey sweep across the left side of the slide.

SPECIAL TESTS

- **Thompson's test** may reveal positive with a grade 3 strain. PG. 1113 Rattray
- **Drop arm test** may reveal positive with a grade 3 supraspinatus strain. PG. 1077 Rattray
- **Yergason's test** may reveal positive with a rupture of the transverse humeral ligament. PG.1078 Rattray



TREATMENT PLAN ACUTE

- **Positioning:** Depends on the location of the strained musculotendinous unit and client's comfort.
- **Hydro:** Ice, RICE to the injured area.
- Treat compensatory structure's, DDB
- Lymphatic drainage techniques are used.
- Effleurage, petrissage, O&I, are indicated proximal if a limb is treated.
- If the injury is on the neck or trunk, the synergists and antagonists are tx'd.
- On-site work is CI'd.
- Stroking and mm squeezing are used distally for all grades.
- Mid range passive relaxed ROM is used on the proximal joints



TREATMENT PLAN EARLY SUB-ACUTE

- **Positioning:** Depends on the location of the strained musculotendinous unit.
- **Hydro:** Cold/warm contrast. If edema is present, elevate limb.
- Treat compensatory structures, DDB
- Proximal lymphatic drainage.
- Proximal limb is treated with effleurage and petrissage, O&I, GTO, agonist contraction.
- TP's are treated using mm stripping.
- Grade 1, on-site work consists of palmer kneading and finger tip kneading.



TREATMENT PLAN EARLY SUB-ACUTE

- **Grade 2 and 3**, on-site work is restricted to light stroking and vibrations. If a hematoma is present, on-site work is delayed.
- Mid-range passive relaxed ROM is used on the proximal and distal joints to the strain.
- In a limb, distal techniques are restricted to stroking and muscle squeezing.



TREATMENT PLAN LATE SUB-ACUTE

- **Positioning:** Depends on the location of the strained musculotendinous unit. If edema is present, elevate the limb.
- **Hydro:** Cold/hot contrast local to the injury. If acute inflammation recurs, return to using local cold hydro.
- Treat compensatory structures, DDB
- Lymphatic drainage techniques decreased due to edema diminishes at this stage.
- Proximal limb is tx'd to reduced Hypertonicity, TP's are tx'd with mm stripping and ischemic compressions to the clients P tolerance.
- **Grade 3 strain:** Ischemic compressions are used instead of heat and stretching

A dark grey arrow points to the right from the left edge of the slide. Below it, several thin, curved lines in shades of blue and grey sweep across the left side of the slide.

TREATMENT PLAN LATE SUB-ACUTE

- **Grade 1 and 2:** the on-site focus shifts to reducing adhesions. Myofascial techniques such as skin rolling and longitudinal mm stripping.
- **Frictions** are used on adhesions, followed by stretch 30 seconds +, Ice the area up to 5 mins.
- **Joint play techniques** to the proximal and distal joints are now introduced.
- **Mid- to full range passive relaxed ROM** on proximal and distal joints. Stretching the painful range last.
- Effleurage and petrissage are now introduced distally.

A dark grey arrow points to the right at the top left. Below it, several thin, curved lines in shades of blue and grey sweep across the left side of the slide.

TREATMENT PLAN CHRONIC

- **Positioning:** Is chosen for comfort and for accessibility to the structures that are treated. Limb is elevated if chronic edema remains.
- **Hydro:** Proximal to the strain includes deep moist heat.
- Treat compensatory structures, DDB
- **Fascial glide** to assess the restrictions, **Fascial techniques** used, such as cross hands or ulnar border spreading.
- **Proximal lymphatic drainage** is indicated, with contrast hydro of alternating hot and cold towels to flush edema.
- Proximal limb is treated with effleurage, petrissage, ischemic compressions.
- Trunk and neck, synergists, and antagonists are tx'd.

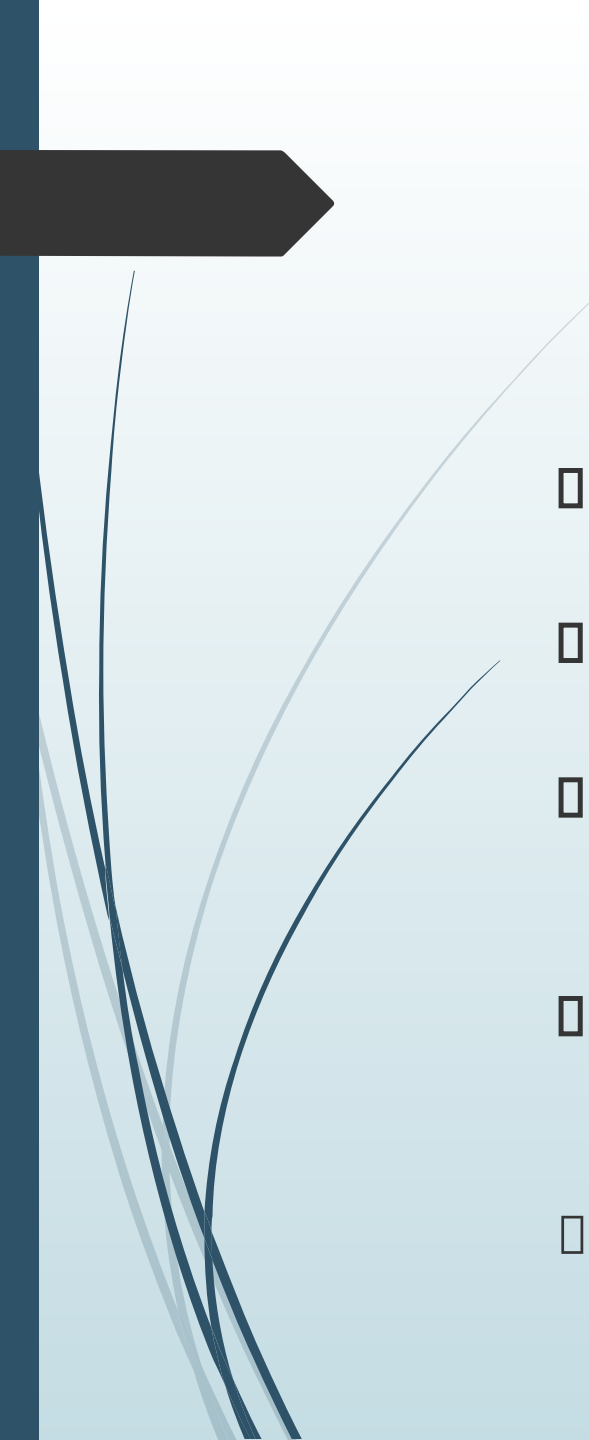


TREATMENT PLAN CHRONIC

- **MM stripping** to reduced adhesions.
- **Grade 1 or 2:** Cross fibre frictions on any adhesions, followed by a stretch 30 seconds +, and Ice up to 5 mins.
- **Joint play** to proximal and distal.
- **Passive relaxed ROM proximal**, distal and affected jts.
- The distal limb is tx'd with effleurage and petrissage.

SELF-CARE

- **Hydro:** Is chosen for the stage of healing.
- **Self massage** in late sub-acute and chronic stages, skin rolling and mm stripping.
- **Remedial exercise:** Gradually strengthen the mm's and tendons.
- Acute stage with a grade 1: perform pain free AROM of distal and proximal joints.
- Grade 2: Submaximal pain-free isometric contractions in inner ranges.
- Grade 3: Physician will recommend exercises and stretching. Remex is CI'd in the acute stage of grades 2 and 3.



SELF-CARE

- **Early sub-acute** with grade 1 and 2: pain free active ROM of distal and proximal joints.
- **Grade 2:** submaximal isometric contractions are gradually increased, from inner-mid ranges.
- **Late sub-acute:** All stretching and strengthening exercises are gradually increased in duration and repetition's. Progressed to isotonic concentric and eccentric exercises.
- **Chronic:** Focus continues on active resisted isotonic concentric and eccentric. Grade 3 strain if there is no cast present, synergists are strengthened.
- Client is encourage to return to the activities that caused the injury on a gradual basis to avoid re-injury.



TREATMENT FREQUENCY & EXPECTED OUTCOME

- Shorter more frequent treatments, 1x/week for chronic stages, re-assess.
- Depending the severity of the injury, TX is used with strengthening exercises, soft tissue work, and immobilization.
- Return to activity, Grade 1-the client can return to the activity with support such as an elastic bandage after 2 days.
- Grade 2 strain-the client can resume activity several days to several weeks after injury.
- Grade 3 strain-immobilization is moved 4-8 weeks. Return to ADL's may be delayed due to mm atrophy.
- ****Please read sample treatment on Pg.303-304**