

# The shoulder

Chapter 17 page 546



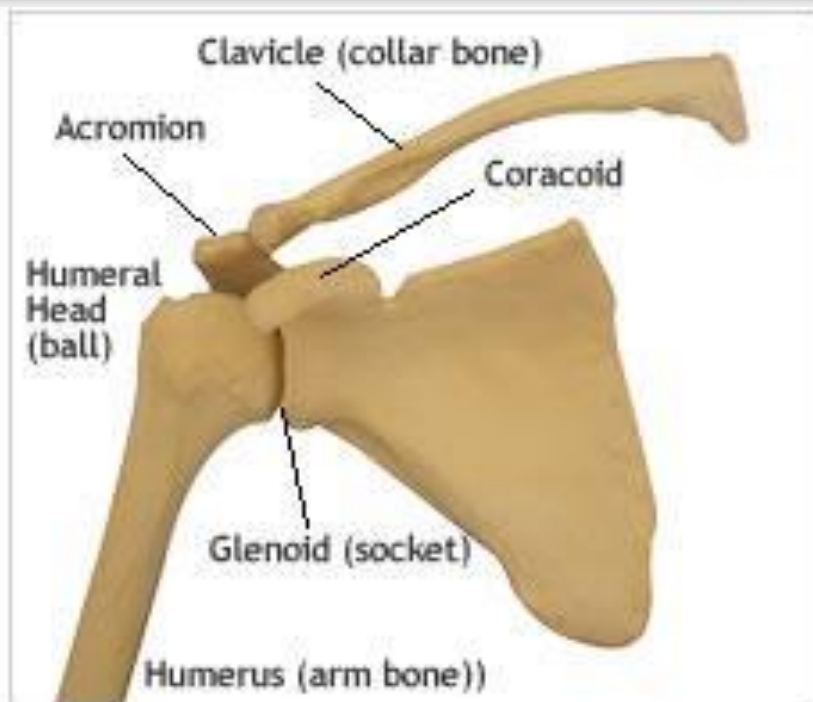
Make sure to  
read pg 547-594

The shoulder complex is composed of 3 main bones: the clavicle, scapula and humerus. It is comprised of 3 synovial joints; the glenohumeral joint, acromioclavicular joint and the sternoclavicular joint, as well as 2 functional articulations; scapulothoracic and suprahumeral. It is designed for mobility and acts in conjunction with the elbow to allow the hand to be moved through a wide range.

The glenohumeral joint is the most mobile and unique joint in the body

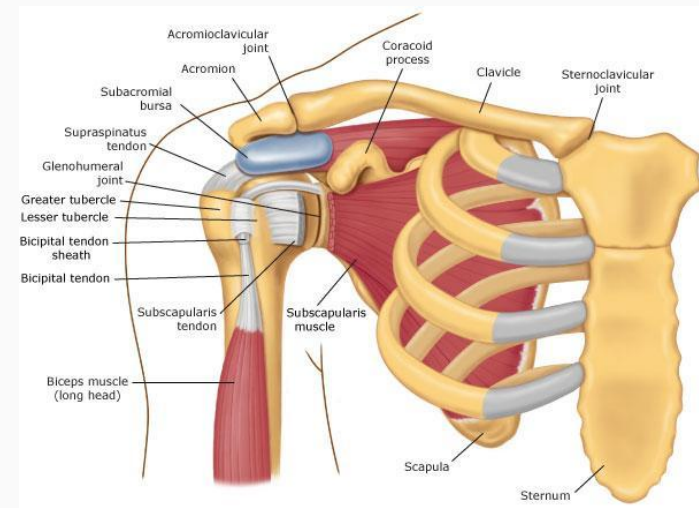
The clavicle acts as a strut, simultaneously linking the arm to the trunk and keeping the arm at a distance from the centre of the body

The scapula acts as a base of support for humeral movements and together with the clavicle increases the ROM of the arm



The absence of bony constraints allows for a wide ROM, but at the expense of stability. Stability is instead provided by various ligaments and the muscular system, hence why properly balanced musculature around the shoulder is so important.

## Shoulder Joints



# Sternoclavicular Joint

Not generally prone to degeneration, subluxation or dislocation due mostly to strong surrounding ligaments. It is the only structural attachment of the upper extremity to the axial skeleton. Its movements are linked to scapular movement. It allows elevation/depression, protraction/retraction and anterior/posterior rotation.

# Acromioclavicular Joint

Allows additional range of scapular movement. Allows for adjustments of the scapula, (i.e. rotation or tipping), and transmits forces from the upper extremity to the clavicle. It allows internal/external rotation, anterior/posterior tipping and upward/downward rotation.

# Glenohumeral Joint

is an incongruous, ball-and-socket triaxial joint. The humeral head is much larger than the glenoid fossa, but the labrum deepens the glenoid fossa to improve congruence. The capsule is loose. As this joint is the most freely moving joint in the body, it is the most susceptible to degeneration and dysfunction. It is also the most commonly dislocated joint in the body.



# Ideal Alignment of the Upper Quadrant

Viewed from behind, the shoulders should rest just below the horizontal axis running through T1. From the side view the plumb line would run directly through the centre of the acromion.

The scapulae should rest flat against the ribs between the 2nd and 7th thoracic vertebrae. The medial border should run parallel to the spine about 3 inches (or 3 of your client's fingers) away from the spine.

The humerus should be in neutral rotation and the top and bottom of the humerus should be in the same vertical plane. Less than 1/3 of the humeral head should protrude in front of the acromion.

# Normal movement patterns

The start position prior to any movement should be as neutral as possible.

The coordination of the scapulae and humeral movements are known as the scapulo-humeral rhythm. (P. 544) The scapula needs to be able to glide properly in order for this to happen, as the rhythm will be impeded if the scapula is fixed.

In flexion the scapula should not wing at any point.

There should be slight elevation of the shoulder during flexion and/or abduction of the arm. The movement should not be initiated with the trapezius.

Scapular position at the end of 180° range of movement of the arm should be slightly depressed, posteriorly tilted and adducted. With thoracic hyperkyphosis or shortened pectoralis minor can make this difficult.

# Continued

Position of the humeral head also affects the shoulder girdle. The humeral head must be stable and centered in the glenoid fossa during movement and the surrounding muscles must be well-balanced to prevent one muscle group from taking over. This can alter the timing of arm movements and the start position of the humerus on the glenoid cavity.

Minimal movement of the spine should occur with flexion and abduction. If there is a thoracic kyphosis present causing the scapulae to be anteriorly tipped, shoulder range of motion may appear to be less than normal. Decreasing the kyphosis would improve range.

The scapula should not adduct during the first 35° of lateral rotation with the arms by the side and elbow flexed. Adduction at this point would indicate rhomboid dominance and an inability or partial inability to control glenohumeral lateral rotation well.

Page 543 for descriptions and images of motions of the scapulae

# Note:

Problems with the scapulae are often related to problems with the neck

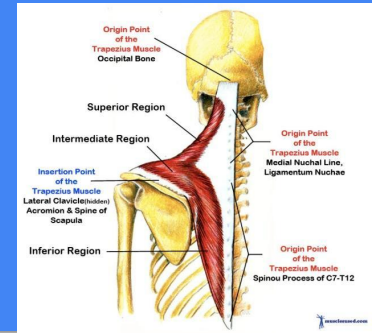
The phrenic nerve emerges from C2, 3 & 4 and feeds into the diaphragm. This can be kept in mind when dealing with car accident victims, as they may experience diaphragm cramping as a result of neck injury.

# Scapulo-Thoracic Muscles

## Common Impairments

Since the shoulder relies so heavily on the musculature for stability, as well as movement, it is imperative that the scapulo-thoracic muscles maintain the correct length, strength and movement patterning. The job of this muscle group is to position the scapula and clavicle and stabilize the scapula during movement.

# Trapezius

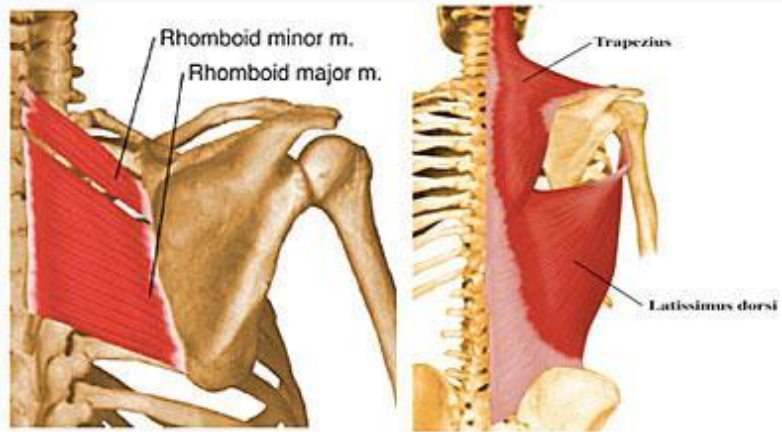


The upper fibers of the trapezius muscles and the levator scapulae elevate the scapulae. If the traps are shortened, they can affect the cervical spine through their ligamentous attachment. Shortness in these muscles will also result in an elevated shoulder, requiring release and stretching. Lengthened muscles will result in the opposite; a depressed shoulder with weak action on the scapula, requiring strengthening.

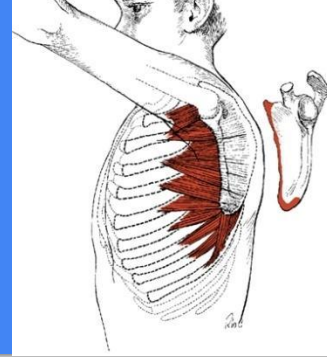
\*Different exercises can be employed for each of the 3 regions of the trapezius muscle based on your client's needs.

# Rhomboids

The Rhomboid muscles act to adduct and downwardly rotate the scapulae. They frequently dominate over the trapezius muscles and can thereby restrict upward rotation of the scapulae.



# Serratus anterior



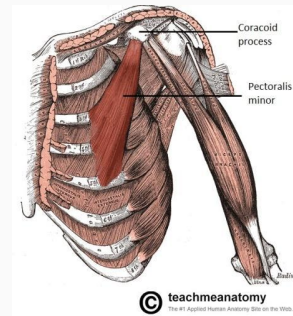
The Serratus anterior works primarily on abducting the scapula and works with the trapezius to upwardly rotate it. It also holds the scapula flat to the rib cage. Many people have weak serratus anterior and never know it until they have an injury. Deficient control of this muscle results in improper timing and impaired range of scapular movement into abduction and lateral rotation. This causes incorrect glenohumeral joint positioning which can then negatively affect the rest of the surrounding musculature.

A cue to encourage serratus activation is to have your client picture their scapula as a taco chip and have them try to scoop the bottom corner toward their chest.



# Pec minor

A common impairment you will see in our age of computers is shortened pec minor. It acts to tilt the scapula anteriorly and caudally (towards the tail,) which allows the inferior edge of the scapula to rotate medially. Shortness of this muscle will limit upward rotation of the scapula. It can also contribute to Thoracic outlet syndrome.

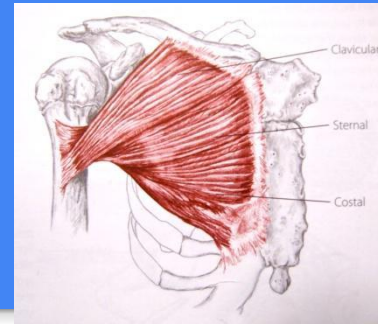


# Thoraco-Humeral Muscles

## Common Impairments

Pectoralis major and Latissimus Dorsi are both very strong muscles in this group. If the length/tension relationship is incorrect or poor neuromuscular patterns arise in these muscles, it can lead to GH joint dysfunction. Shortness can lead to a reduction in range of shoulder flexion and dominance of these muscles over the scapulo-humeral muscles will cause poor control of the humerus in the glenoid cavity.

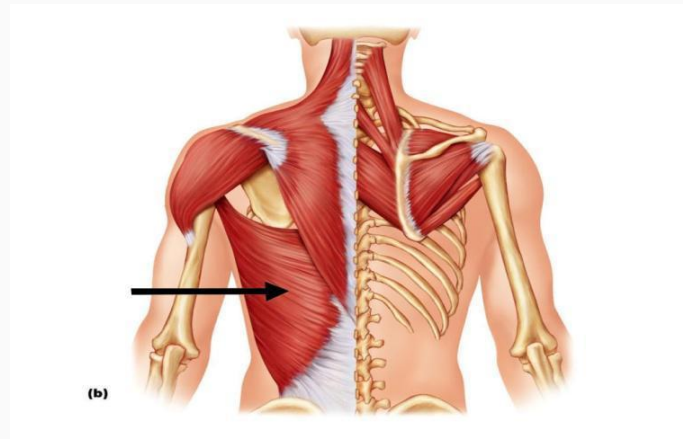
# Pec major



Adducts and medially rotates the humerus. The upper fibers flex and horizontally adduct the shoulder, while the lower fibers depress the shoulder girdle via the attachments on the humerus. If pec major is not properly opposed by subscapularis, it can result in an anterior glide of the humeral head, restricting the shoulder girdle elevation that should naturally accompany shoulder

# Latissimus Dorsi

Medially rotates, adducts and extends the shoulder. Also acts to depress the shoulder girdle. When used bilaterally, these muscles can also help extend the spine and anteriorly tilt the pelvis. If shortened, it will limit shoulder abduction and flexion.



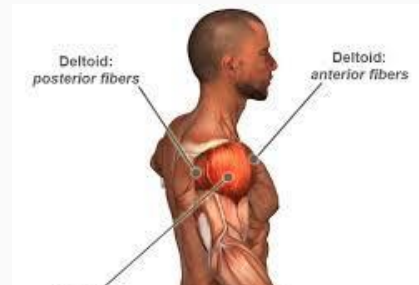
# Scapulo-Humeral Muscles

## Common Impairments

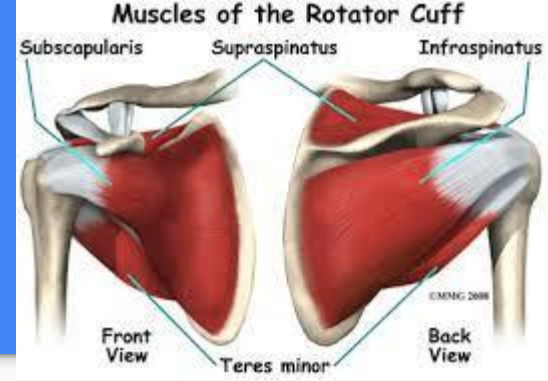
These muscles counterbalance the other 2 muscle groups acting on the shoulder girdle. This allows for optimal control of the humerus in its neutral position. The most common impairments involve lateral rotator muscles shortening, poor timing and strength in lateral rotator muscles causing impingement. Other impairments include poor neuromuscular timing and strength of subscapularis, deltoid muscle dominance and/or tightness in the rotator cuff affecting the shoulder joint capsule.

# Deltoids

Act to abduct the humerus. The anterior portion flexes and medially rotates the humerus. The middle portion abducts the arm and the posterior portion extends and laterally rotates it. If too dominant, it will pull the humeral head superiorly during shoulder abduction. As depressors of the humeral head, the rotator cuff muscles should counterbalance the deltoids if everything functions properly.



# The rotator cuff



SITS: **Supraspinatus** abducts and laterally rotates the shoulder and depresses and stabilizes the humerus. **Infraspinatus** and **teres minor** act to laterally rotate and depress the humeral head. **Subscapularis** medially rotates the humerus, depresses the head and pulls it posteriorly, counterbalancing the muscles trying to cause anterior and superior glide of the humerus.

Shortened Supraspinatus mimics a shortened deltoid causing shoulder depression and GH abduction, which may result in Supraspinatus impingement due to compression forces. Shortened Infraspinatus and teres minor cause tightening of the posterior capsule, interfering with posterior glide, also resulting in impingement. Weakened subscapularis can allow excessive glide of the humeral head, leading to impingement. If subscap is weak, Pectoralis major may also take over as the dominant medial rotator of the humerus, which will cause the humeral head to glide anteriorly and place stress on the anterior capsule during flexion and lateral adduction.

# Exercise progressions

1. Find neutral scapular placement
  - i) Link hands on top of head, elevate the shoulders, abduct the elbows, lower the shoulders and float the arms down to the sides.
2. Correct ribcage/thoracic placement
3. Employ closed chain exercise to start, as this stimulates proprioception and reduces deltoid activity.
4. Scapular control
  - a. Protraction/Retraction
5. Scapular work
  - a. Elevation/depression
  - b. Upward rotation in scaption (halfway between flexion and abduction)
  - c. Ball Wall Walk
6. Rotator cuff
  - a. Ball, foam roller, weighted toning balls
7. Closed chain, Weight-bearing, Resistance
  - a. Puppy in the Snow, 4-point protraction/retraction, Wall push-up
8. Open Chain
  - a. Front and back rowing with a band attached to a free-standing post (flexed elbow and extended) (“Open chain” would be standing or kneeling. Close the chain more by having them sit.)



# Common Dysfunctions of the Shoulder Girdle and Upper Quadrant

Poor Biomechanics caused by poor posture and dysfunctional movement

- poor ergonomics at work
- Weak stabilizers (rotator cuff, serratus anterior, trapezius)

The Plan

- restore good posture/alignment
- Low load, closed chain with slow, controlled, pain-free movements
- non-weightbearing, progress to using moveable props in sitting, progress to weightbearing

Example: Protract/retract, Lat Pull/Press, I's, Y's and T's, wall slides

Shoulder Instability, meaning some portion of the stability mechanism is dysfunctional.

-Usually presents with forward translation of the humeral head on the glenoid, compromising comfort and function.

-Is often accompanied by popping, clicking, grinding in range of motion.

### The Plan

- low load, closed chain

- small ROM, pain-free

- correct upper quadrant biomechanics

Example: protract/retract with closed rotator cuff strengthening, scapular stabilization.

Rotator Cuff Injuries/Impingement Syndrome usually involves the Supraspinatus muscle/tendon.

-Impingement occurs when the greater tuberosity compresses tissues under the coracoacromial arch.

-Supraspinatus is compressed and can tear. Calcifications can develop. Subacromial bursitis may also occur.

-A final result may be bicipital tendinopathy, where the tendon of the long head of the biceps brachii becomes irritated.

-Pain may be present with both passive and active ROM in all cases with deeper pain at the insertion of the muscle, usually between 60° and 120° of elevation where impingement happens.

## The Plan

-correct biomechanics of upper quadrant

-ensure pain-free ROM, low load, closed chain

-make use of the scaption plane for exercises

-control of the shoulder and humerus should be mastered before progressing to more difficult functional exercises/sports/work activities

Example: Scapular isolations using a prop such as a pole or flex-band, supraspinatus stretches.

Adhesive Capsulitis, otherwise referred to as “Frozen Shoulder”.

- Limits all shoulder movement
- Is the result of inflammation, scarring and thickening in the GHJ and its surrounding capsule
- Is difficult to treat and generally involves a lengthy rehabilitation process

## The Plan

- Correct biomechanics in upper quadrant
- low load, closed chain
- use passive ROM and pain-free active ROM
- Establish neutral shoulder as much as possible
- Strengthen local stabilizers
- support arms where able (props)

Examples: Protraction/retraction, possibly on the wall, possibly using weights (1lb-2lb), Elevation/depression, pendulum exercises (using gravity), wall circles

Thoracic Outlet Syndrome is in a similar category.

- There is abnormal compression of the neurovascular bundle between the cervical spine and the lower border of the axilla
- There may also be a compression of the subclavian artery or the brachial plexus
- Symptoms are paresthesia, (tingling/pricking,) or aching over the whole arm
- Often caused by poor posture, ergonomics and/or biomechanics
- Aggravated by lifting, carrying, gripping, possibly weightbearing on hands or playing instruments

-Muscle atrophy may affect the intrinsic muscles of the hand

The Plan

- Improve posture and correct biomechanics
- Avoid overhead activities and exercises. May need to avoid sleeping prone.
- Pain-free ROM, closed chain, avoid weight-bearing
- Check breath patterns and add some diaphragmatic breathing to lessen the use of accessory respiratory muscles
- Gentle, gradual chest openers with support props
- Ensure neck is always well supported in neutral. May need pillows to place upper body into flexion so neck and pectorals don't over-engage

The Plan

-Breathing with a flex-band around the ribs, elevation/depression, ball wall walk, basic core strengthening exercises. Similar exercises to what you would give someone with poor posture, but avoiding weight on the hands or gripping a prop.

# Exercise interventions for the shoulder girdle

Acute and early  
subacute stages  
of tissue healing

# Early motion of the GH joint

Pg 594

Wand exercises

Ball rolling or table top dusting

Wall (window) washing

Pendulum/ codman's exercise

“Gear shift” exercises



# Early motion of scapula

PROM and AAROM of scap are in chapter 3

During the acute phase, sidelying is usually more comfortable than prone if pt can perform active scap elevation/depression and protraction/retraction use sitting position

# Early neuromuscular control

Pg 596

Frequently , the rot cuff muscles are inhibited after trauma or surgery. Initiate the following to stimulate activation and develop control as soon as pt can tolerate it.

**Multiple- angle muscle setting**

**Protected weight bearing**

# Self stretching to increase shoulder ROM

Page 597

Low intensity prolonged stretch

**To increase flexion and horizontal adduction: cross-chest stretch**

**To increase flexion and elevation of the arm**

**To increase external rotation**

**To increase internal rotation**

**To increase abduction and elevation of the arm**

**To increase internal rotation, extension and scapular tilting**

# Manual and self stretching exercises for specific muscles

Page 599

**To stretch the latissimus dorsi muscle**

**To stretch the pectoralis major muscle**

**To stretch the pectoralis minor muscle**

**To stretch the levator scapulae muscle**

**To stretch the upper trapezius muscle**

Exercise  
development and  
improve muscle  
performance and  
functional control

# Serratus anterior strength

Page 602

Scapulothoracic and GH musculature control is fundamental to correcting pathomechanics of the shoulder girdle and for improving strength, muscle endurance, power, and performance of functional activities.

# Isometric exercises

Page 602

Applied along a continuum of very gentle to max contraction, and are applied at varying muscle lengths by changing joint angles.

**Scapular muscles**

**Multiple-angle isometrics: GH muscles**

**Self-applied multiple-angle isometrics**

# Stabilization exercises

Page 604

Application of alternating isometrics and rhythmic stabilization techniques is designed to develop strength and stability of proximal muscle groups in response to shifting load

**Open-chain stabilization exercises for the scapular muscles**

**Open-chain stabilization exercises for the shoulder girdle**

**Static closed-chain stabilization exercises**

**Dynamic closed-chain stabilization exercises**



# Dynamic strengthening exercises: scapular muscles

Page 607

Stabilization of the thorax, neck and scapula are imperative before initiating dynamic strengthening exercises.

**Scapular retraction**

**Scapular depression**

**Scapular upward rotation with depression**

# Dynamic strengthening exercises: glenohumeral muscles

Page 611

**Shoulder external rotation**

**Shoulder internal rotation**

**Shoulder abduction and elevation of the arm in scapular plane**

**Shoulder flexion**

**Shoulder adduction**

**Shoulder horizontal adduction**

**Shoulder extension**

**Elbow flexion**

**Exercise using diagonal movement patterns**

# Functional progression for the shoulder complex

Page 614

An essential element of shoulder rehab and injury prevention program is a sequence of carefully progressed exercises and activities

**Exercises using combined movement patterns with functional activities**

**Equipment**

**Integration of functional activities**

Independent  
learning activities  
page 616 due  
next class