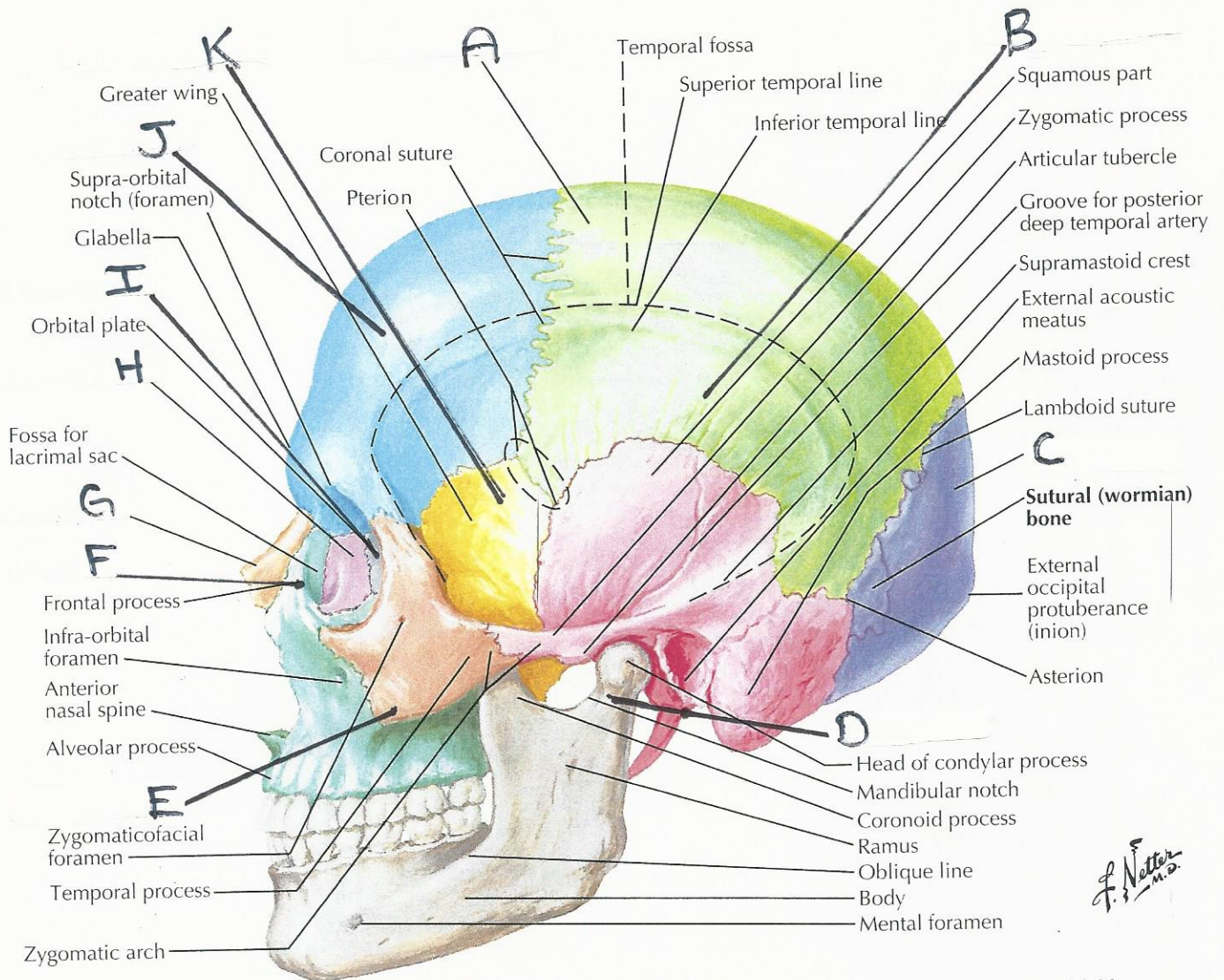
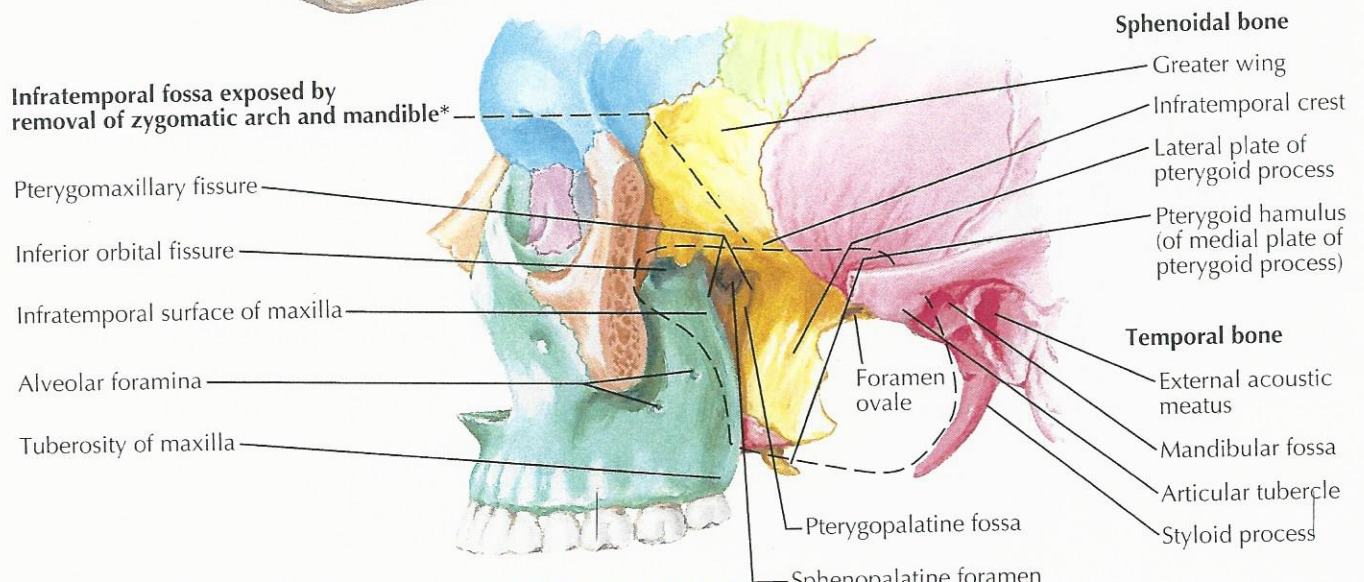


Skull: Lateral View

See also Plates 7, 8, 15



F. Netter M.D.



Skull: Midsagittal Section

See also Plates 37, 39

