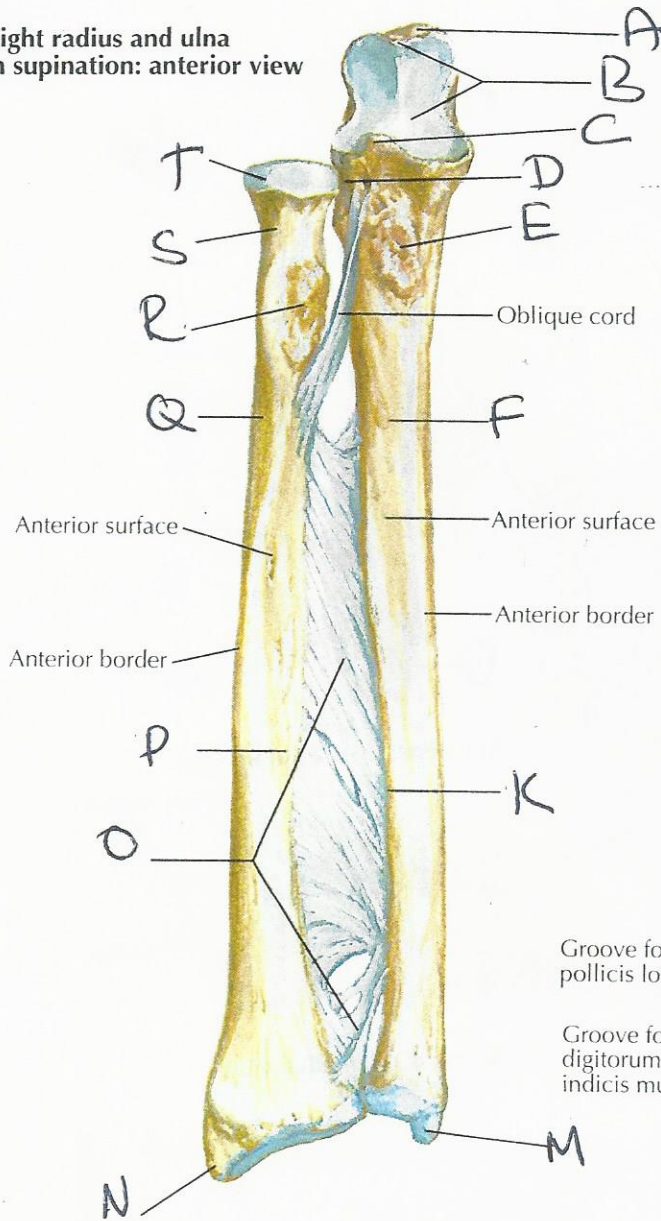


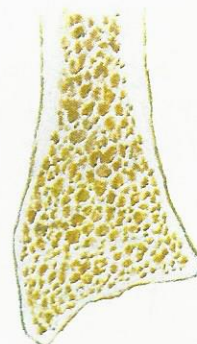
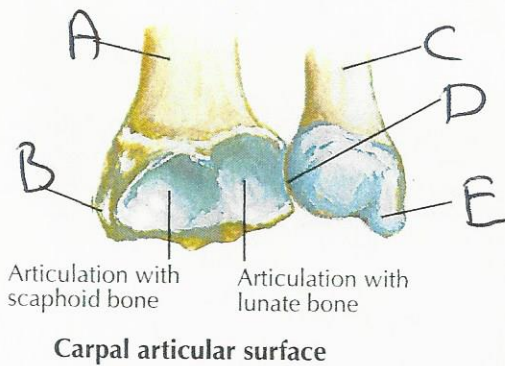
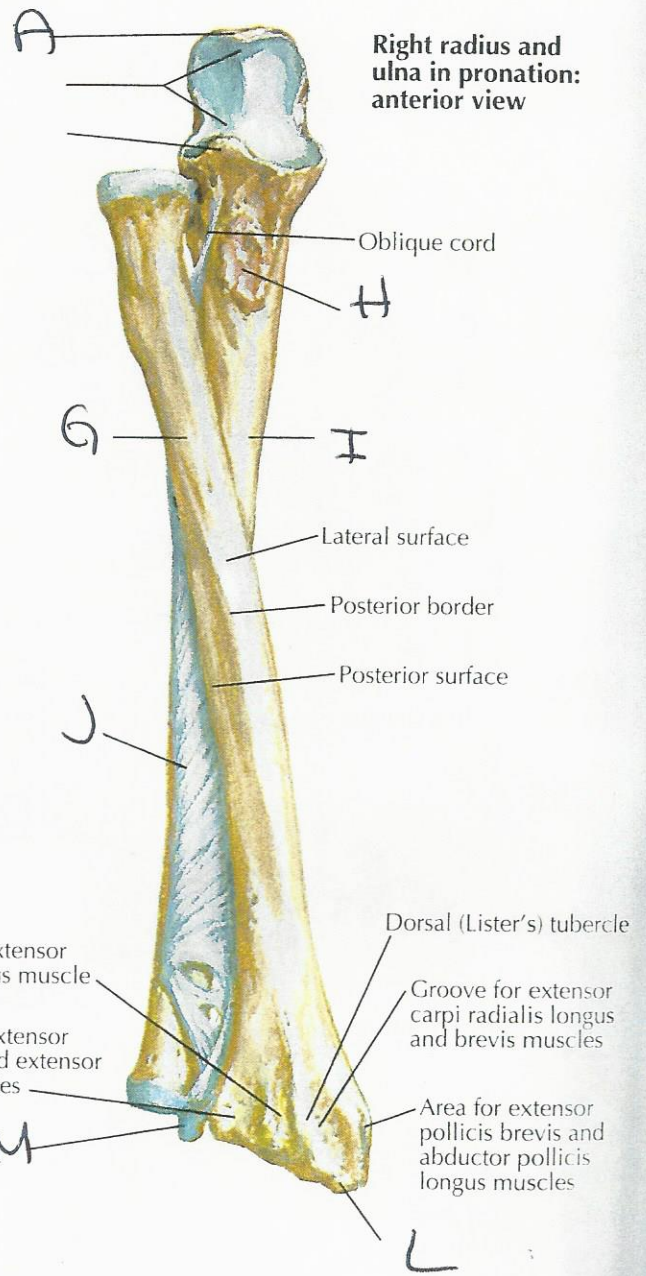
Bones of Forearm

See also Plates 439, 442

Right radius and ulna in supination: anterior view



Right radius and ulna in pronation: anterior view



Coronal section of radius demonstrates how thickness of cortical bone of shaft diminishes to thin layer over cancellous bone at distal end

F. Netter M.D.