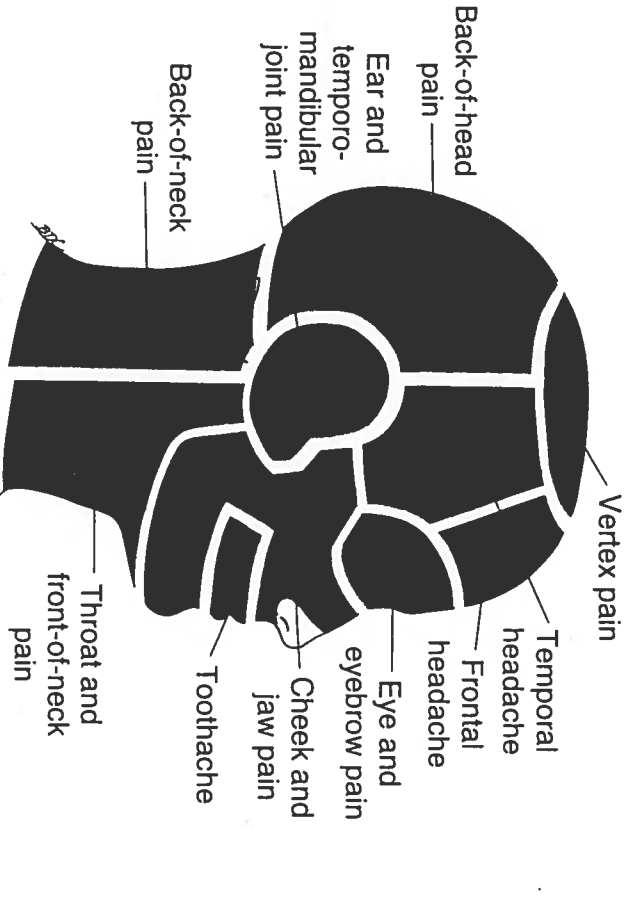
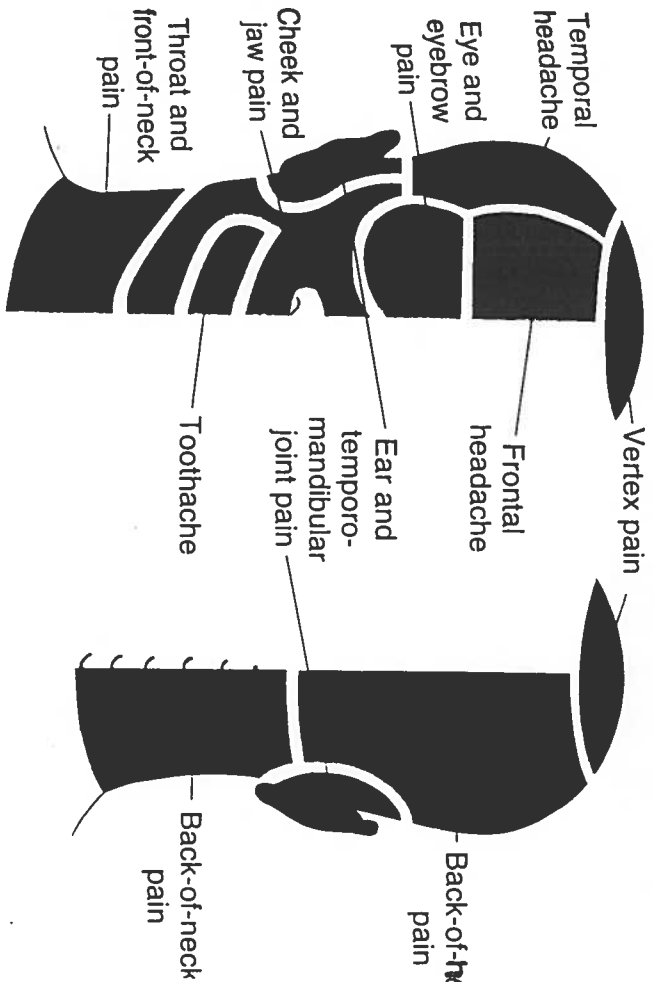
PAIN GUIDE

VERTEX PAIN

- Sternocleidomastoid (sternal) (7)
- Splenius capitis (15)

BACK-OF-HEAD PAIN

- Trapezius (TrP₁) (6)
- Sternocleidomastoid (sternal) (7)
- Sternocleidomastoid (clavicular) (7)
- * Semispinalis capitis (16)
- * Semispinalis cervicis (16)
- Splenius cervicis (15)
- Suboccipital group (17)
- Occipitalis (14)

TEMPORAL HEADACHE:

- * Digastric (12)
- Temporalis (TrP₂) (9)

TEMPORAL HEADACHE:

- Trapezius (TrP₁) (6)
- Sternocleidomastoid (sternal) (7)
- Temporalis (TrP_{s,2,3}) (9)
- Splenius cervicis (15)
- Suboccipital group (17)
- * Semispinalis capitis (16)

FRONTAL HEADACHE

- Sternocleidomastoid (clavicular) (7)
- Sternocleidomastoid (sternal) (7)
- * Semispinalis capitis (16)
- Frontalis (14)

*** Zygomaticus major (13)**

EAR AND TEMPOROMANDIBULAR JOINT PAIN

- Lateral pterygoid (11)
- Masseter (deep) (8)
- Sternocleidomastoid (clavicular) (7)
- Medial pterygoid (10)

EYE AND EYEBROW PAIN

- Sternocleidomastoid (sternal) (7)
- Temporalis (TrP₁) (9)
- Splenius cervicis (15)
- Masseter (superficial) (8)
- Suboccipital group (17)
- Occipitalis (14)
- Orbicularis oculi (13)
- Trapezius (TrP₁) (6)

CHEEK AND JAW PAIN

- Sternocleidomastoid (sternal) (7)
- Masseter (superficial) (8)
- Lateral pterygoid (11)
- Trapezius (TrP₁) (6)
- Masseter (deep) (8)
- Digastric (12)
- Medial pterygoid (10)

*** Buccinator (13)**

*** Platysma (13)**

*** Orbicularis oculi (13)**

*** Zygomaticus major (13)**

TOOTHACHE

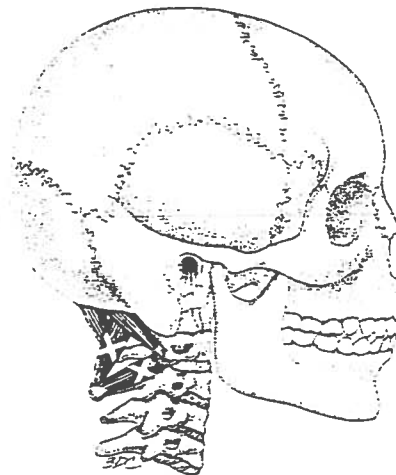
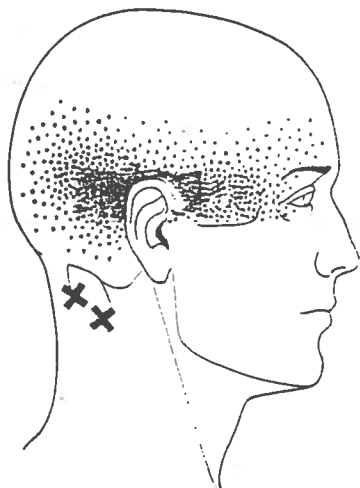
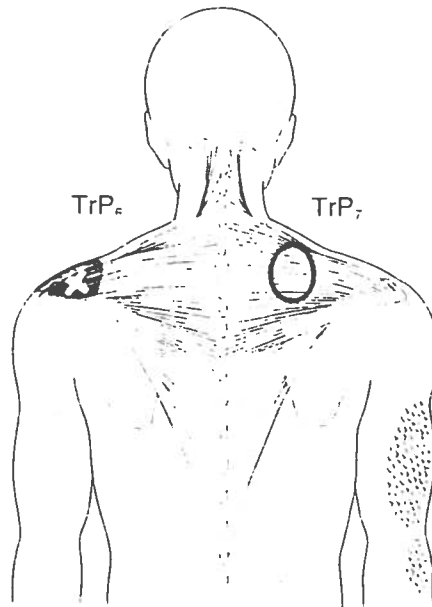
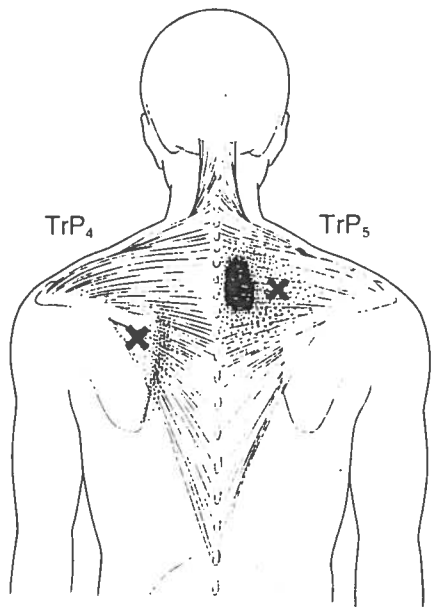
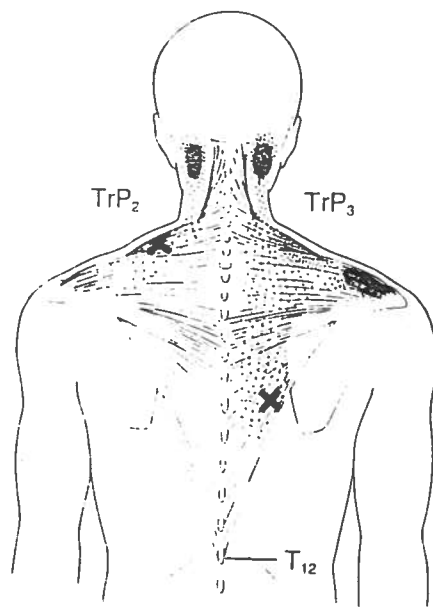
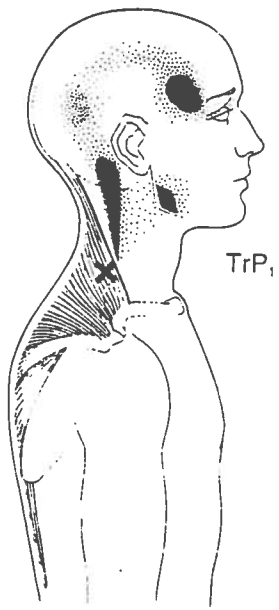
- Temporalis (TrP_{s,2,3}) (9)
- Masseter (superficial) (8)
- * Digastric (anterior) (12)

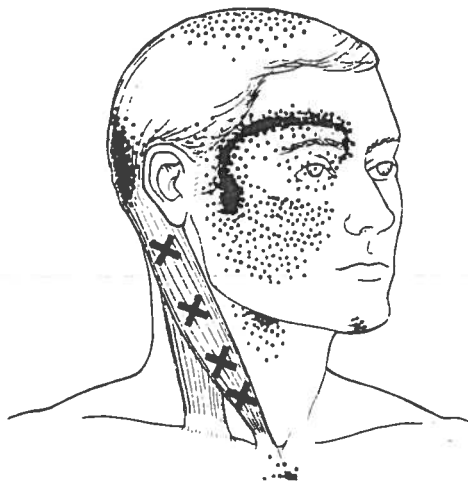
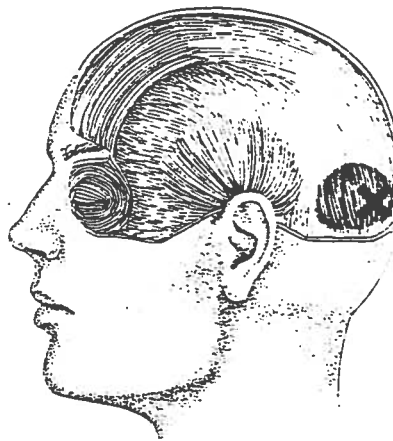
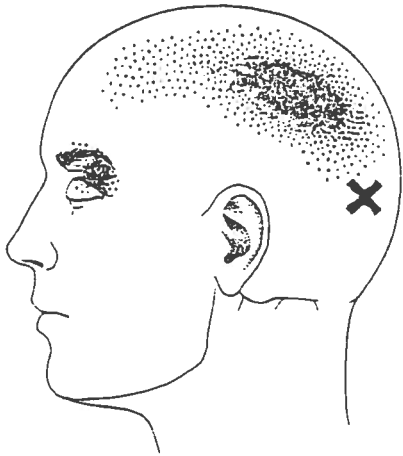
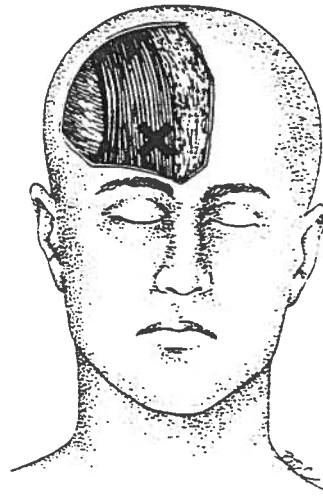
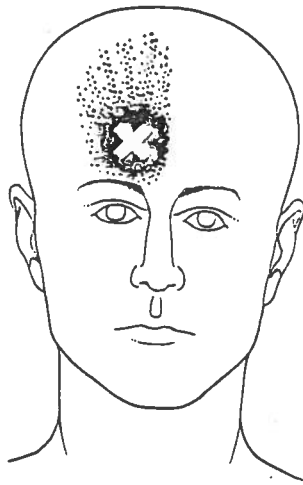
BACK-OF-NECK PAIN

- Trapezius (TrP₁) (6)
- Trapezius (TrP₂) (6)
- Trapezius (TrP₃) (6)
- Multifidi (16)
- Levator scapulae (19)
- Splenius cervicis (15)
- Infraspinatus (22)

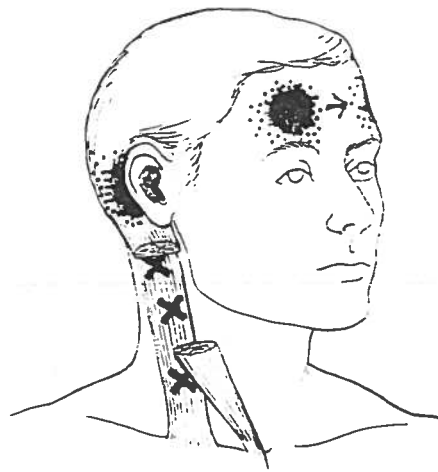
THROAT AND FRONT-OF-NECK PAIN

- Sternocleidomastoid (sternal) (7)
- * Digastric (12)
- Medial pterygoid (10)

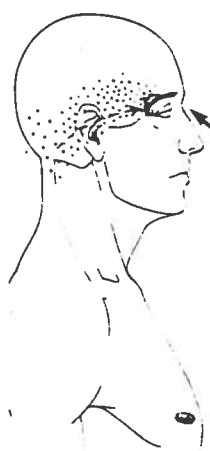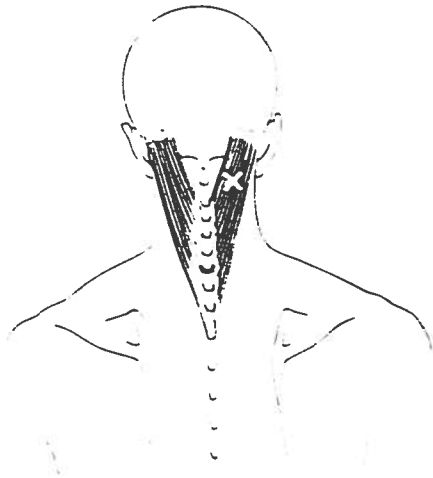




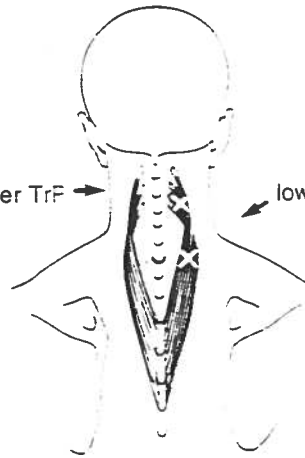
Sternal division



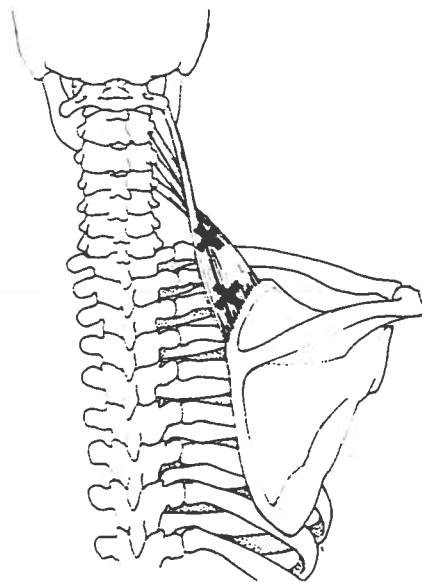
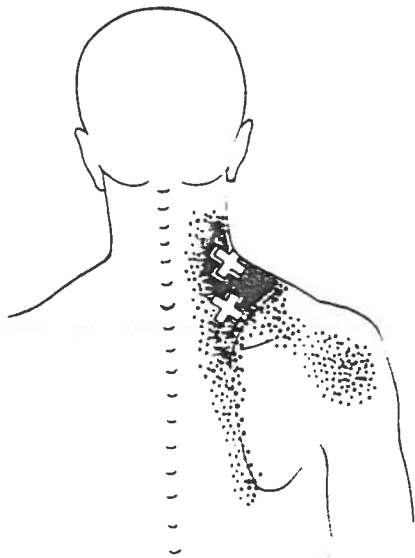
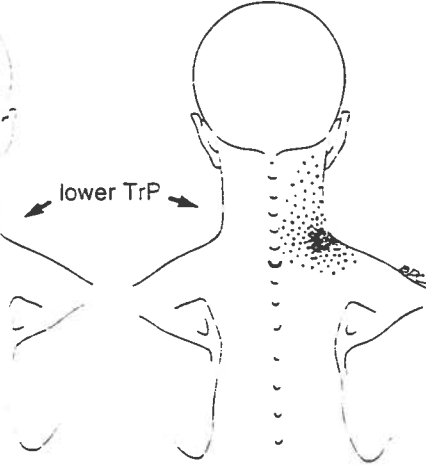
Clavicular division


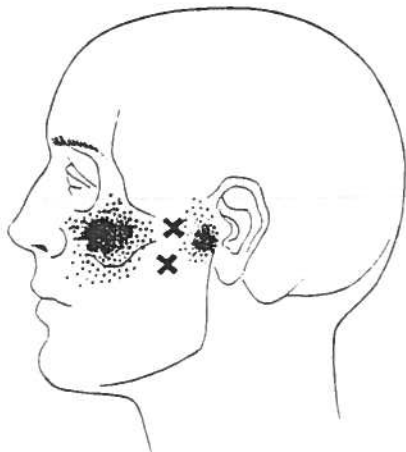
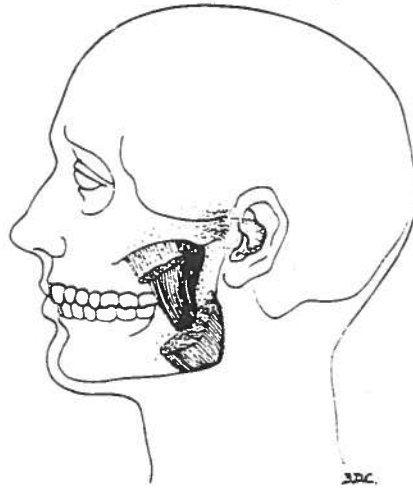
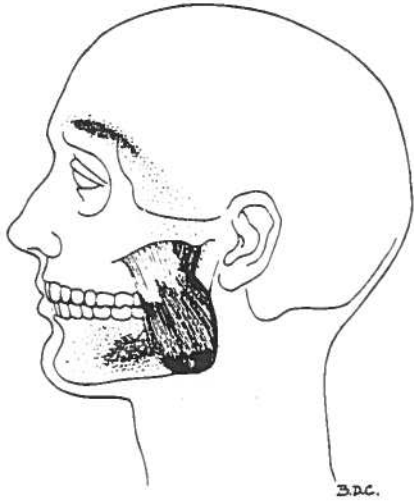
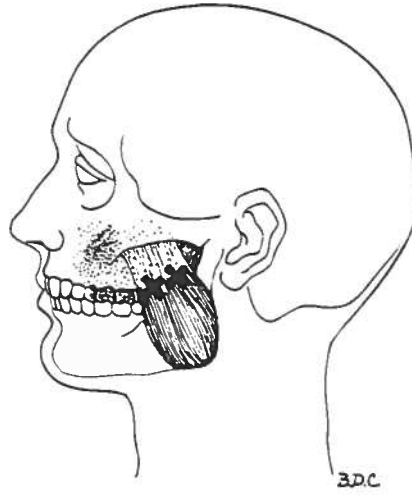
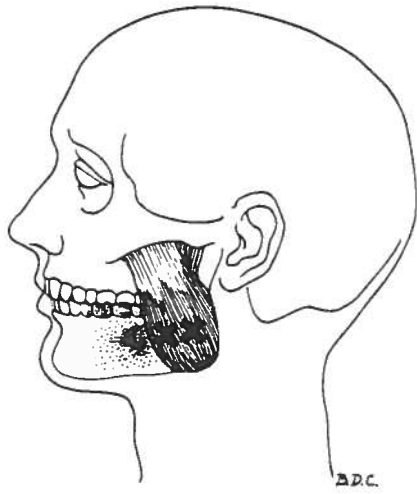


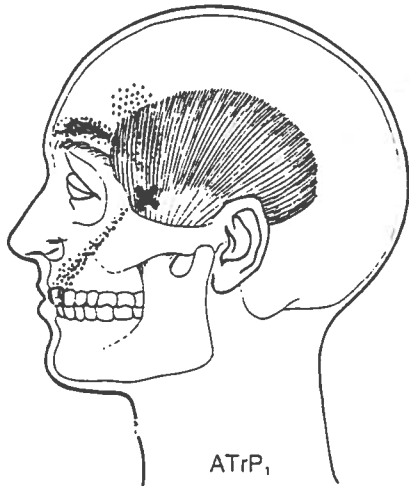
upper TrF



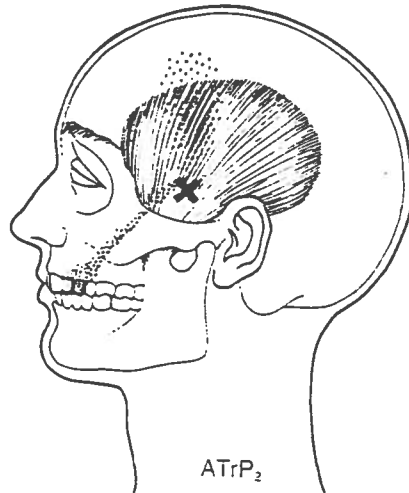
lower TrP



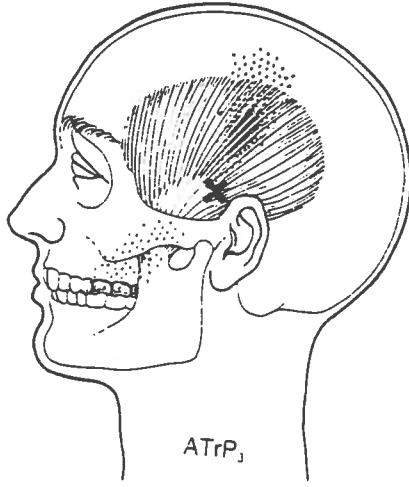




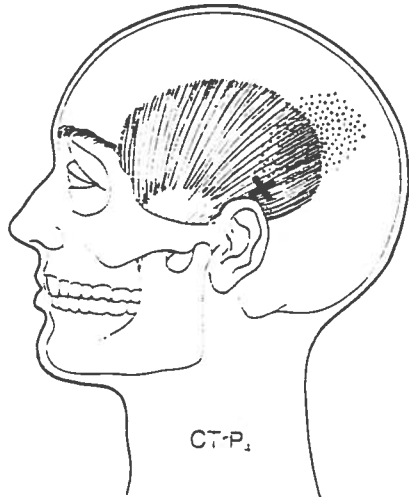
ATrP₁



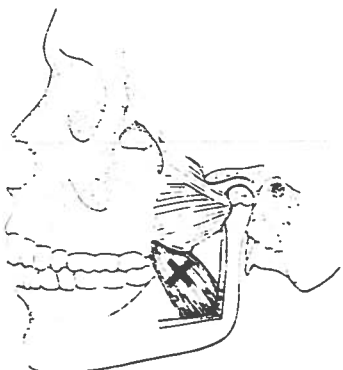
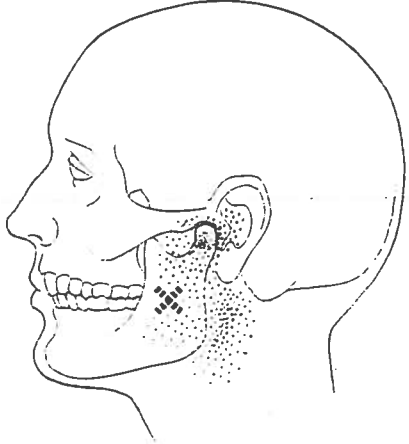
ATrP₂



ATrP₃



CT-P₁



PAIN AND MUSCLE GUIDE

UPPER-THORACIC BACK PAIN

Scaleni (20)
Levator scapulae (19)
Supraspinatus (21)
Trapezius (TrP₂ and TrP₃) (6)
Trapezius (TrP₃) (6)
Multifidi (48)
Rhomboides (27)
Splenius cervicis (15)
Triceps brachii (TrP₁) (32)
Biceps brachii (30)

BACK-OF-SHOULDER PAIN

Deltoid (28)
Levator scapulae (19)
Scaleni (20)
Supraspinatus (21)
Teres major (25)
Teres minor (23)
Subscapularis (26)
Serratus posterior superior (47)
Latissimus dorsi (24)
Triceps brachii (TrP₁) (32)
Trapezius (TrP₃ and TrP₄) (6)
Iliocostalis thoracis (48)

BACK-OF-ARM PAIN

Scaleni (20)
Triceps brachii (TrP₁ and TrP₃) (32)
Deltoid (28)
Subscapularis (26)
Supraspinatus (21)
Teres major (25)
Teres minor (23)
Latissimus dorsi (24)
Serratus posterior superior (47)
Coracobrachialis (29)
Scalenus minimus (20)

MID-THORACIC BACK PAIN

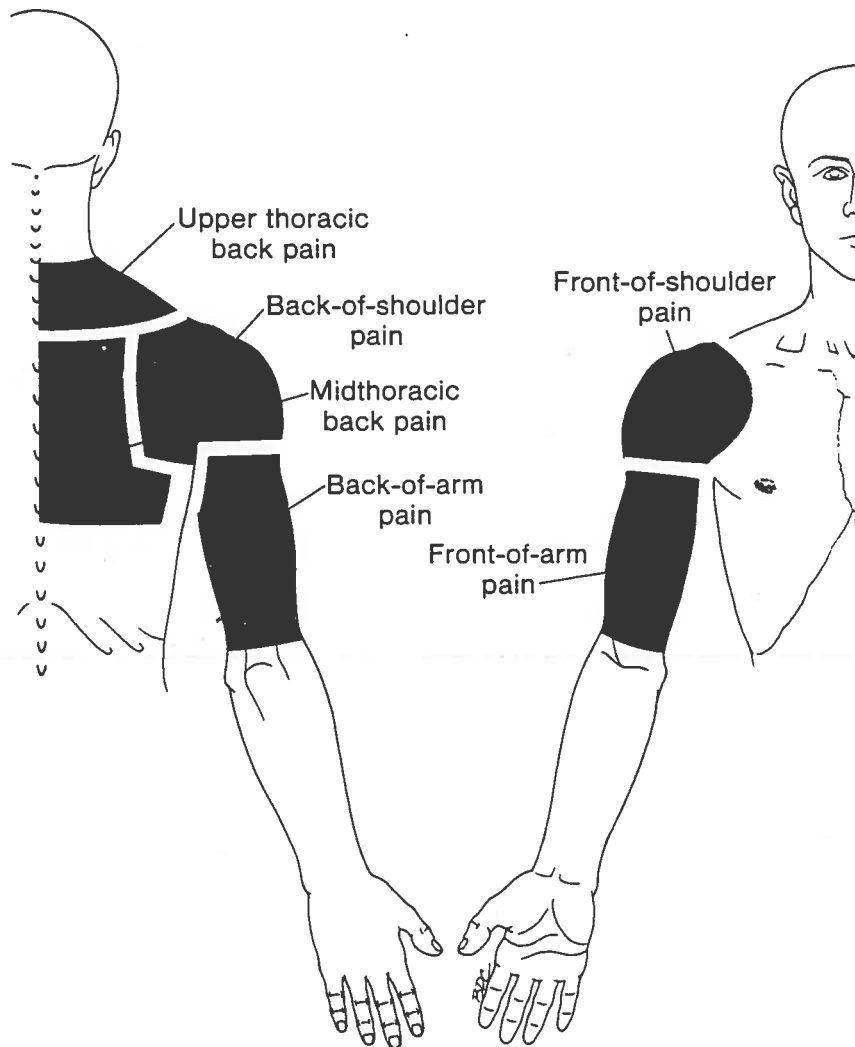
Scaleni (20)
Latissimus dorsi (24)
Levator scapulae (19)
Iliocostalis thoracis (48)
Multifidi (48)
Rhomboides (27)
Serratus posterior superior (47)
Infraspinatus (22)
Trapezius (TrP₄) (6)
Trapezius (TrP₅) (6)
Serratus anterior (46)

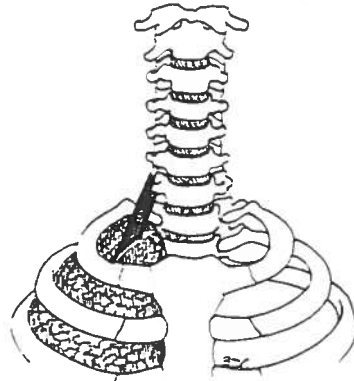
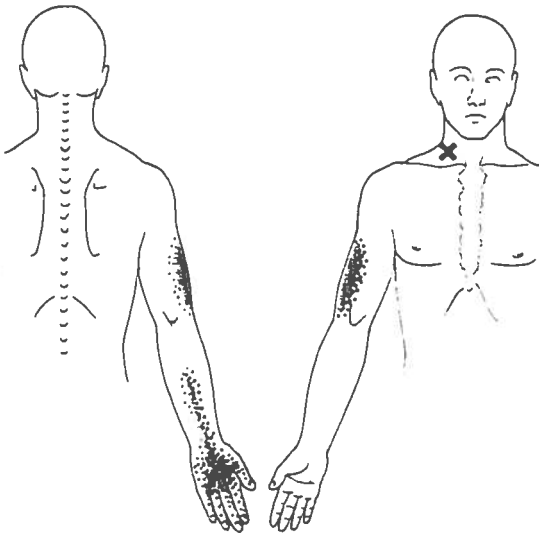
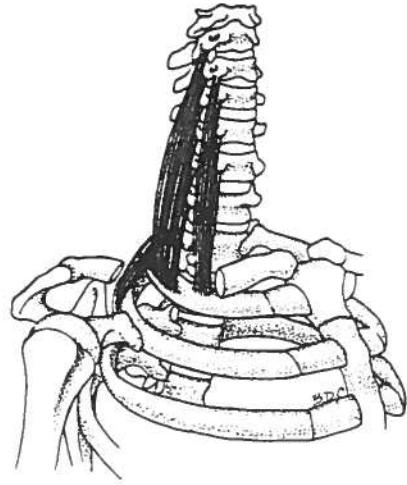
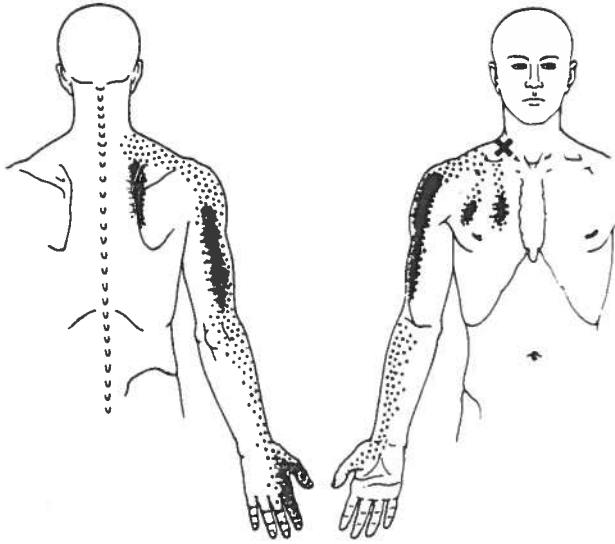
FRONT-OF-SHOULDER PAIN

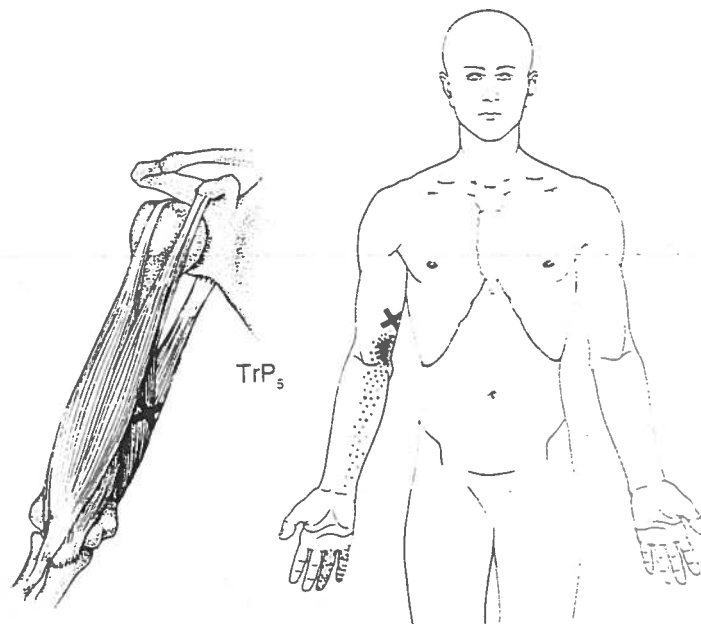
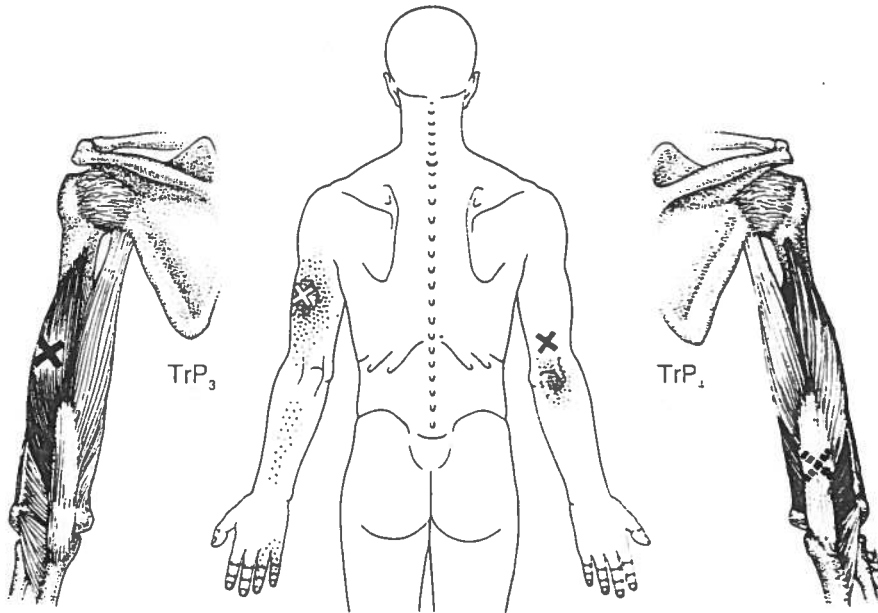
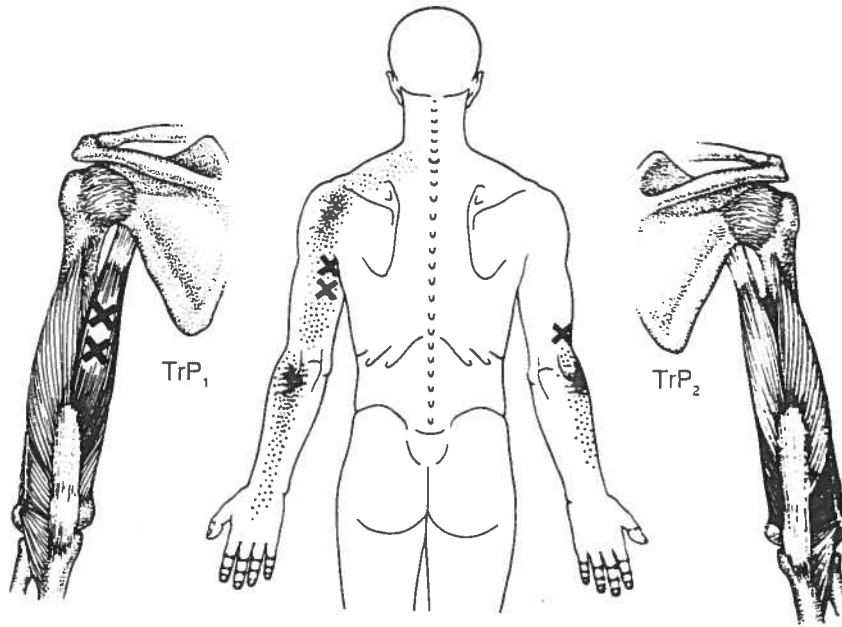
Infraspinatus (22)
Deltoid (28)
Scaleni (20)
Supraspinatus (21)
Pectoralis major (42)
Pectoralis minor (43)
Biceps brachii (30)
Coracobrachialis (29)
Sternalis (44)
Subclavius (42)
Latissimus dorsi (24)

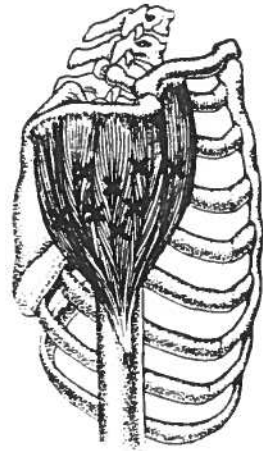
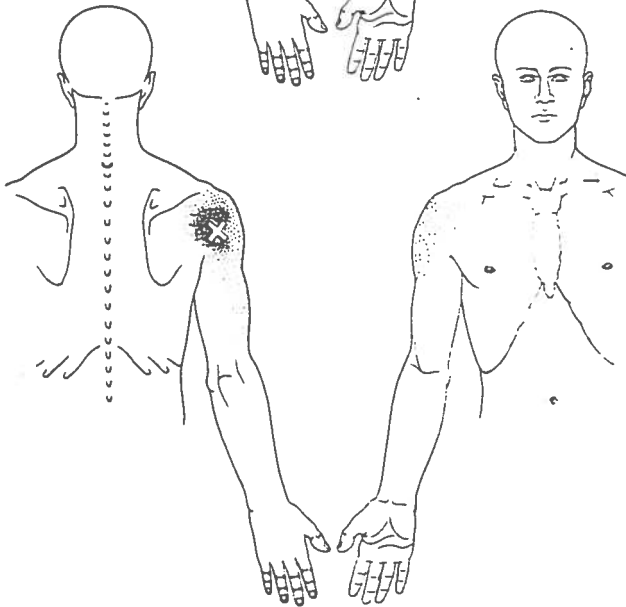
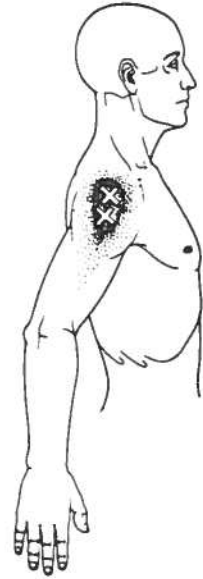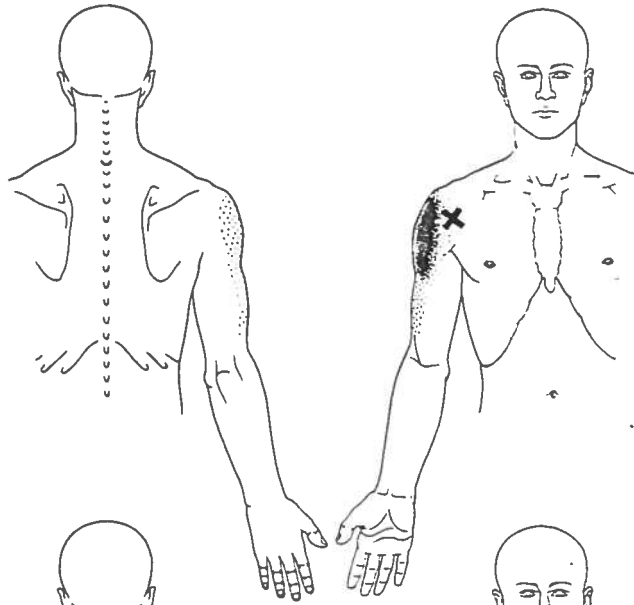
FRONT-OF-ARM PAIN

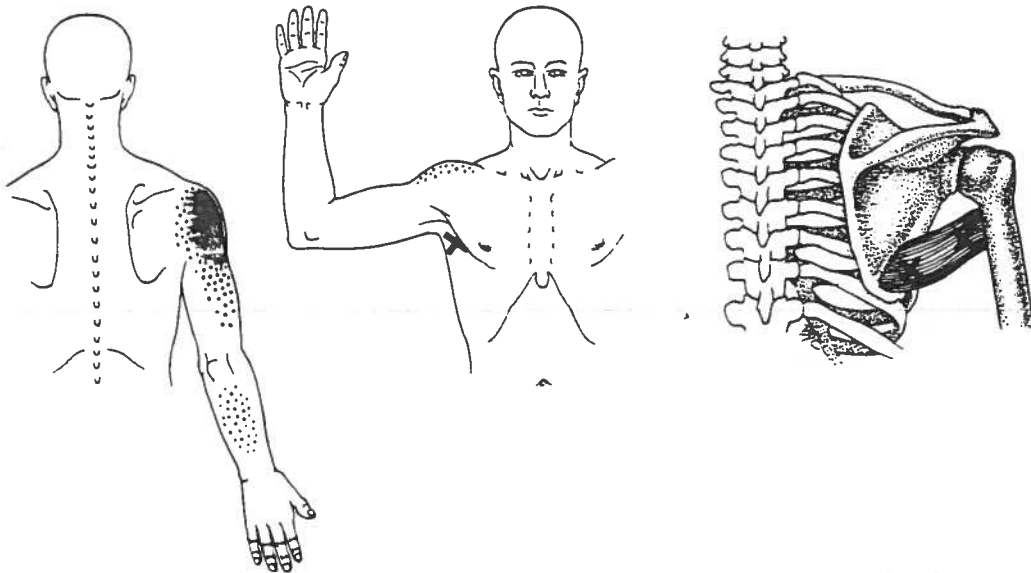
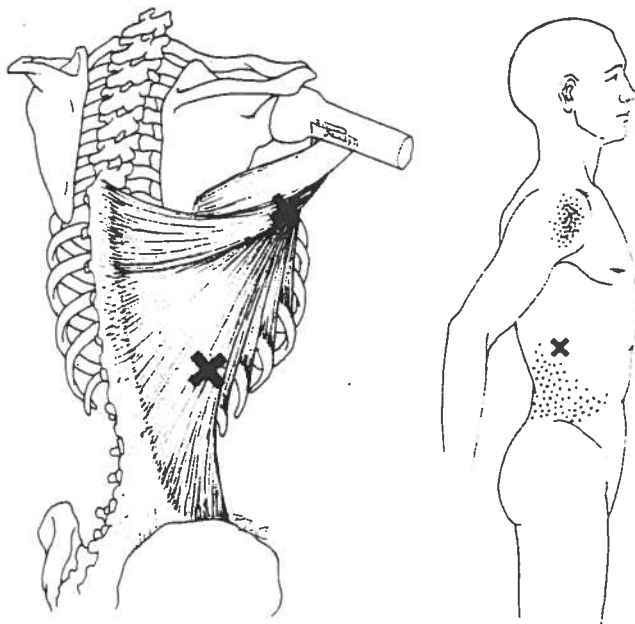
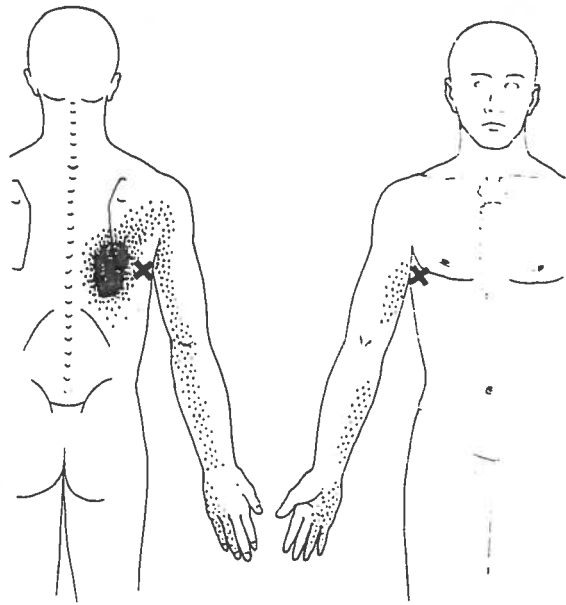
Scaleni (20)
Infraspinatus (22)
Biceps brachii (30)
Brachialis (31)
Triceps brachii (TrP₃) (32)
Supraspinatus (21)
Deltoid (28)
Sternalis (44)
Scalenus minimus (20)
Subclavius (42)

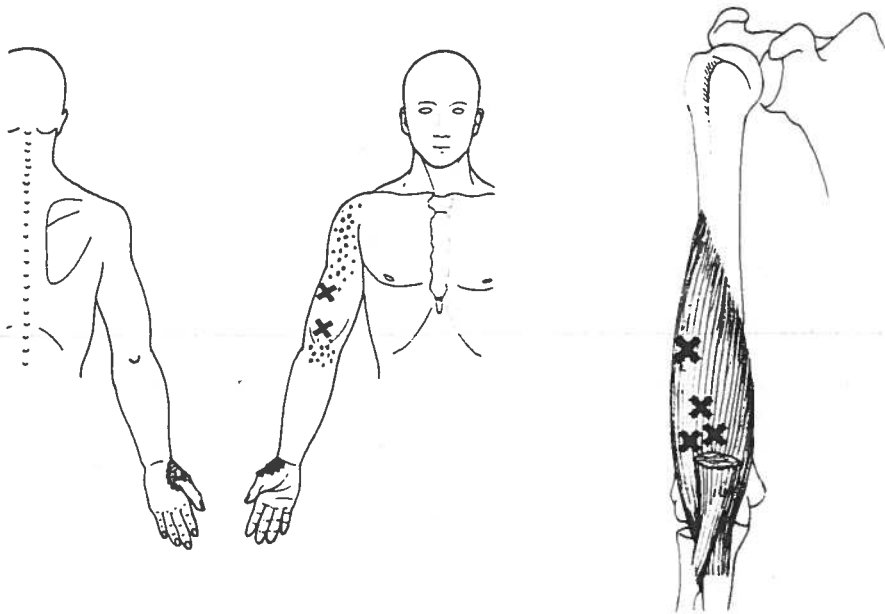
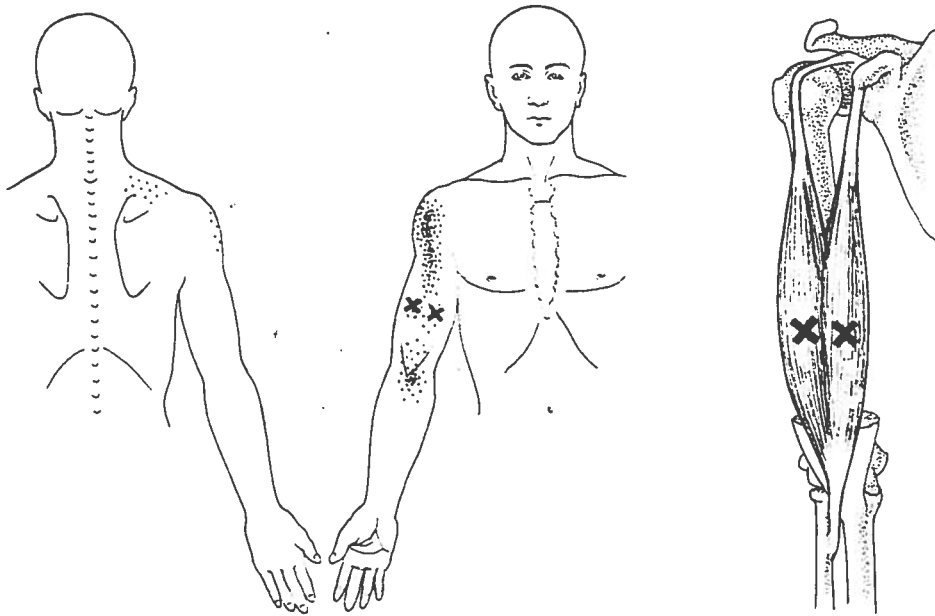
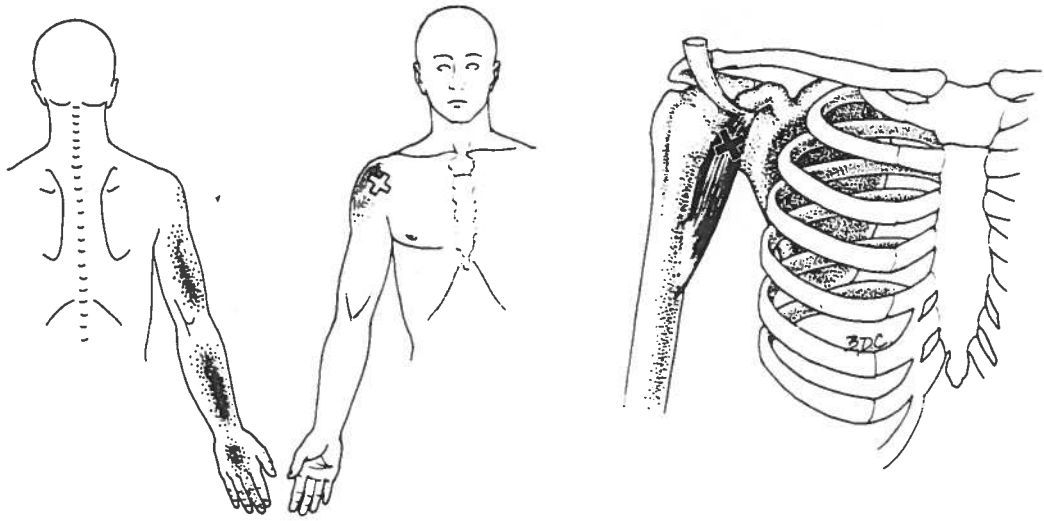


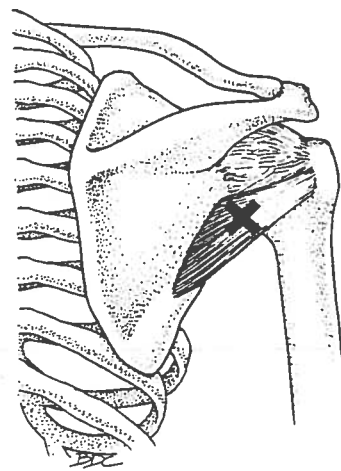
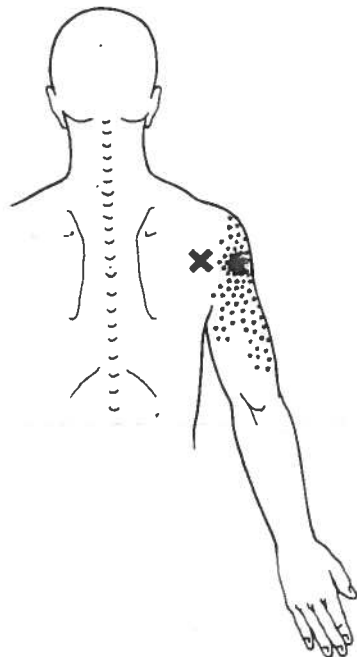
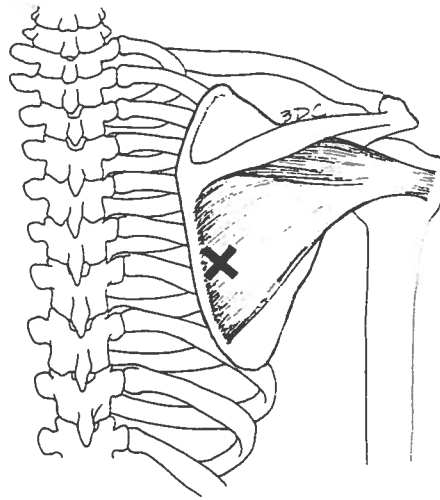
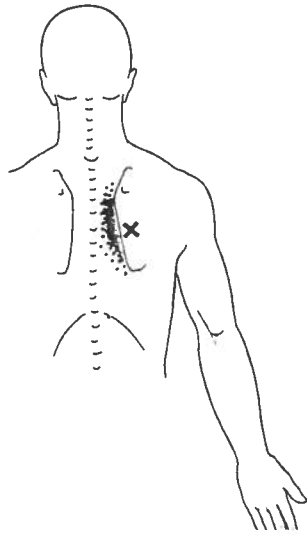
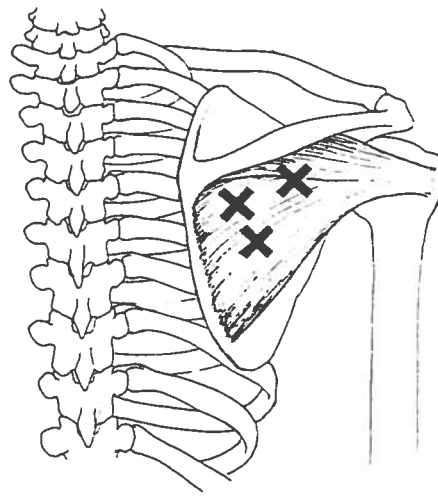
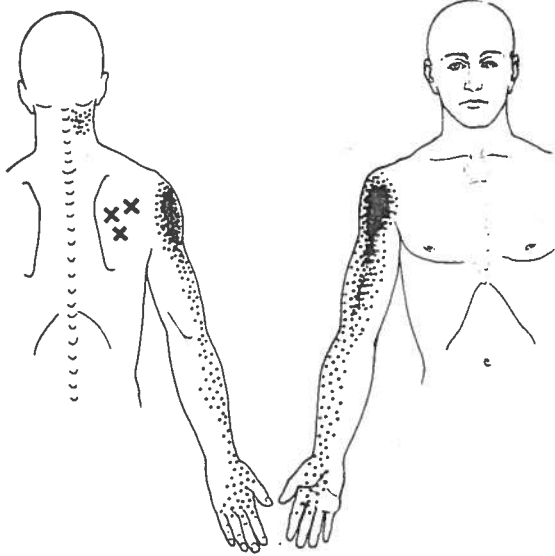


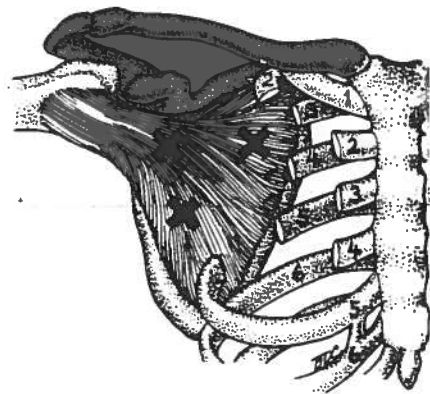
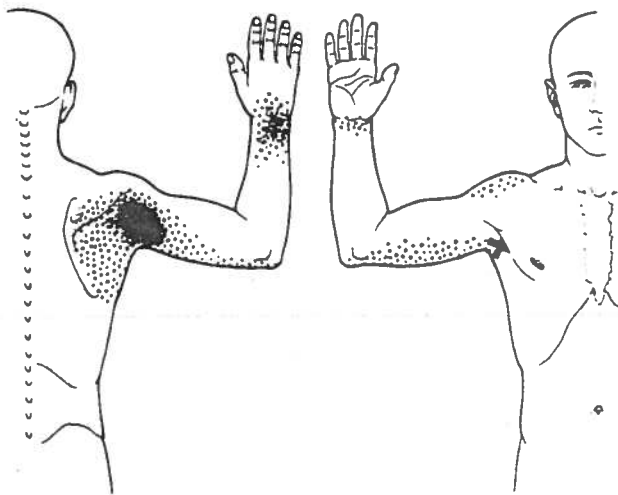
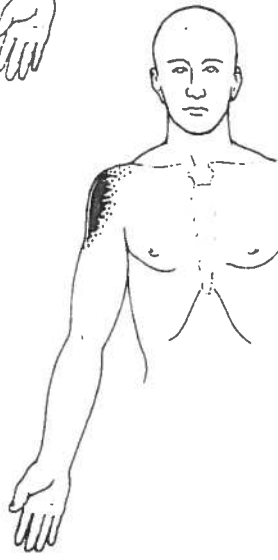
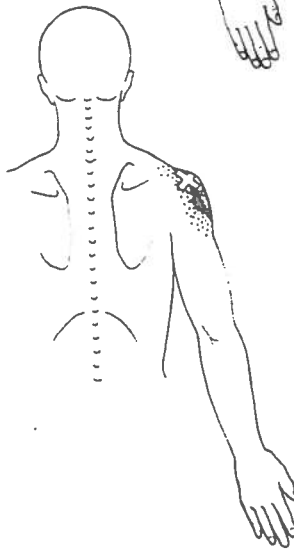
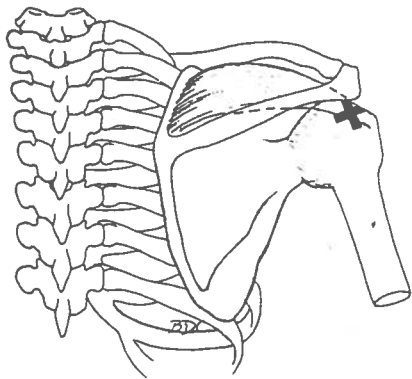
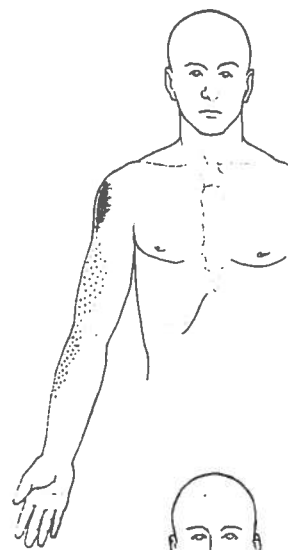
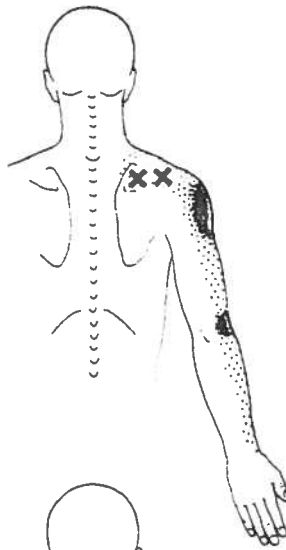
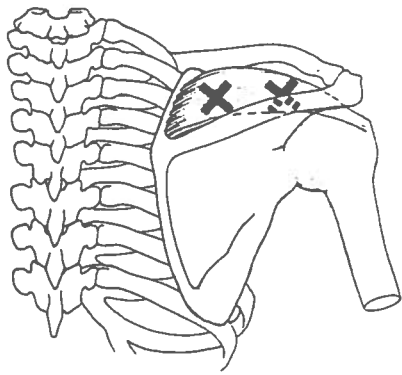


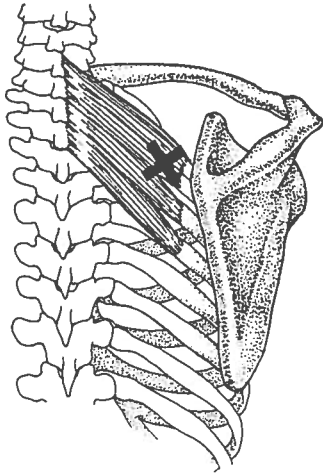
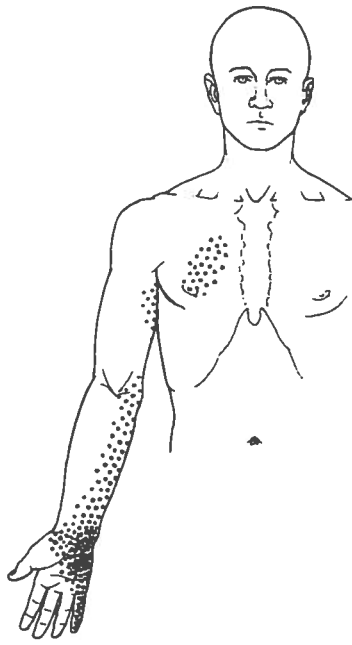
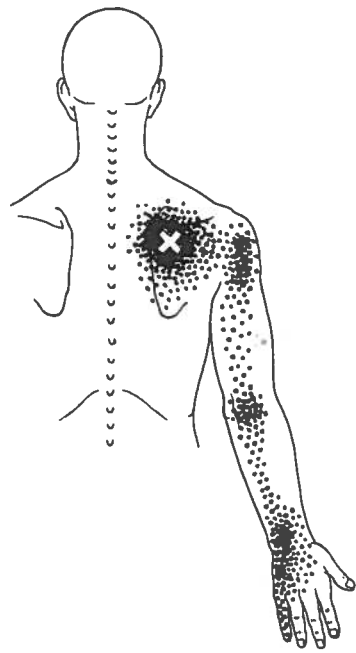




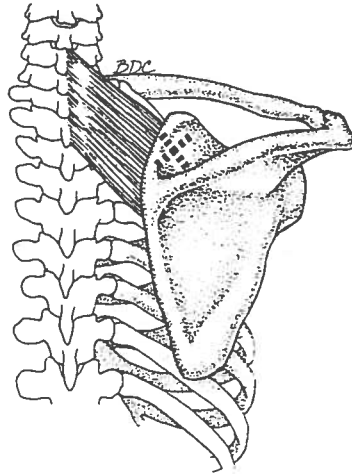




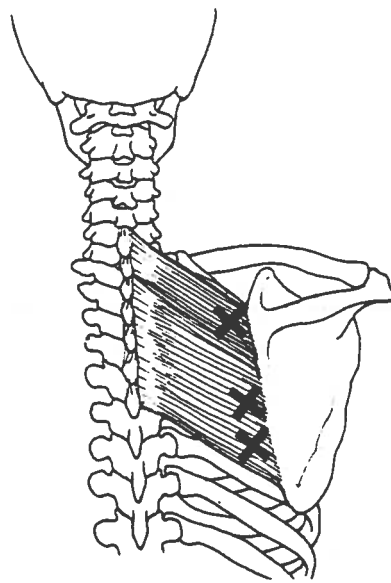
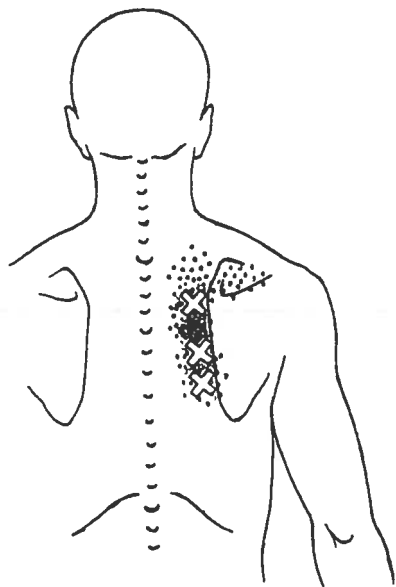


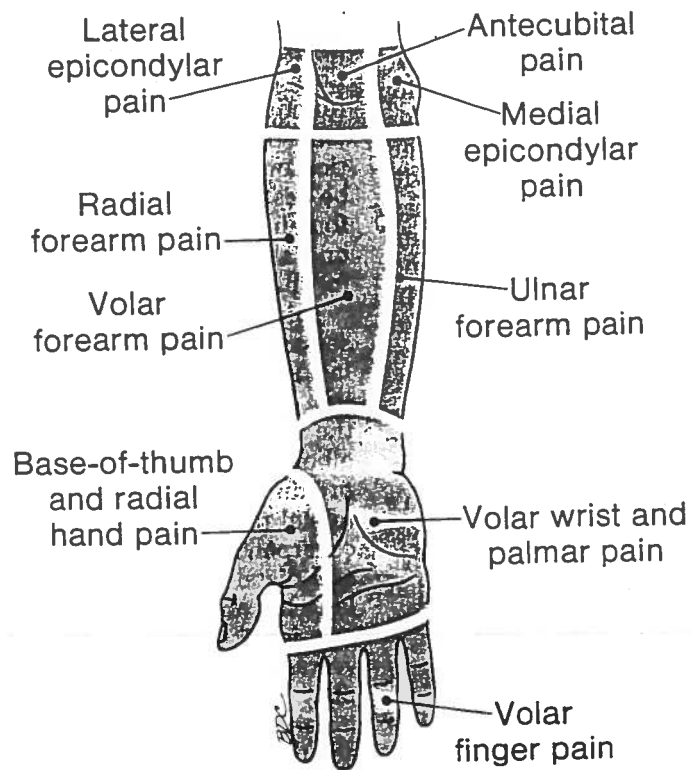
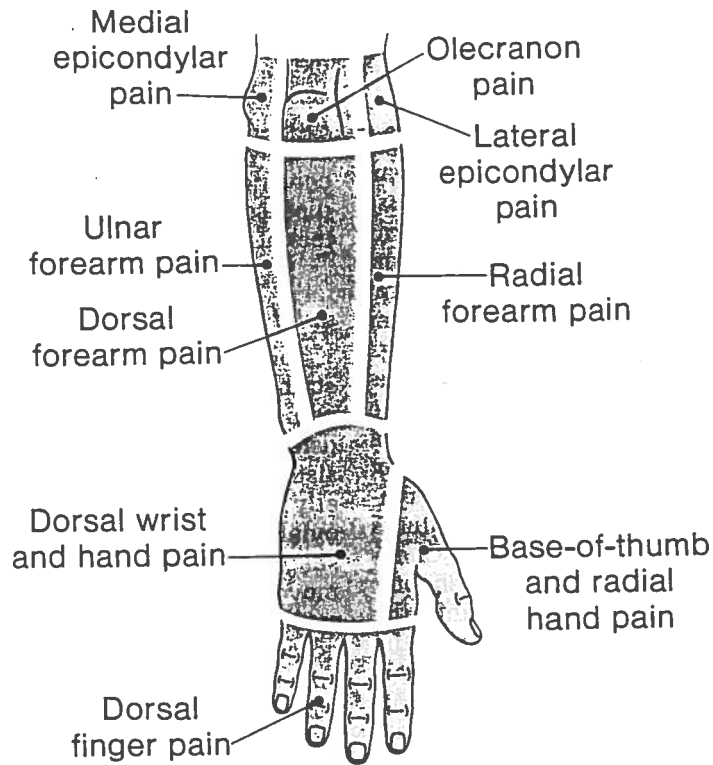


Trigger point palpable



Trigger point not palpable





PAIN GUIDE

ANTECUBITAL PAIN

Brachialis (31)
Biceps brachii (30)

BASE-OF-THUMB AND RADIAL HAND PAIN

Supinator (36)
Scaleni (20)
Brachialis (31)
Infraspinatus (22)
Extensor carpi radialis longus (34)
Brachioradialis (34)
Opponens pollicis (39)
Adductor pollicis (39)
Subclavius (42)
First dorsal interosseus (40)
Flexor pollicis longus (38)

DORSAL FINGER PAIN

Extensor digitorum (35)
Interossei (40)
Scaleni (20)
Abductor digiti minimi (40)
Pectoralis major (42)
Pectoralis minor (43)
Latissimus dorsi (24)
Subclavius (42)

DORSAL FOREARM PAIN

Triceps brachii (TrP₁₋₃) (32)
Teres Major (25)
Extensores carpi radialis longus and brevis (34)
Coracobrachialis (29)
Scalenus minimus (20)

DORSAL WRIST AND HAND PAIN

Extensor carpi radialis brevis (34)
Extensor carpi radialis longus (34)
Extensor digitorum (35)
Extensor indicis (35)
Extensor carpi ulnaris (34)
Subscapularis (26)
Coracobrachialis (29)
Scalenus minimus (20)
Latissimus dorsi (24)
Serratus posterior superior (47)
First dorsal interosseus (40)

LATERAL EPICONDYLAR PAIN

Supinator (36)
Brachioradialis (34)
Extensor carpi radialis longus (34)
Triceps brachii (TrP₂) (32)
Supraspinatus (21)
Fourth and fifth finger extensors (35)
Anconeus (32)

MEDIAL EPICONDYLAR PAIN

Triceps brachii (TrP₃) (32)
Pectoralis major (42)
Pectoralis minor (43)
Serratus anterior (46)
Serratus posterior superior (47)

OLECRANON PAIN

Triceps brachii (TrP₁) (32)
Serratus posterior superior (47)

RADIAL FOREARM PAIN

Infraspinatus (22)
Scaleni (20)
Brachioradialis (34)
Supraspinatus (21)
Subclavius (42)

ULNAR FOREARM PAIN

Latissimus dorsi (24)
Pectoralis major (42)
Pectoralis minor (43)
Serratus posterior superior (47)

VOLAR FINGER PAIN

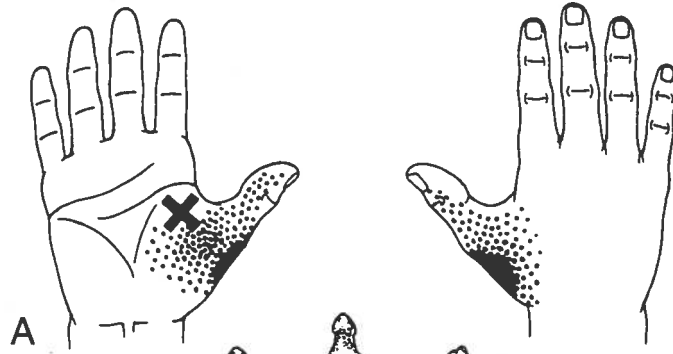
Flexores digitorum superficialis and profundus (38)
Interossei (40)
Latissimus dorsi (24)
Serratus anterior (46)
Abductor digiti minimi (40)
Subclavius (42)

VOLAR FOREARM PAIN

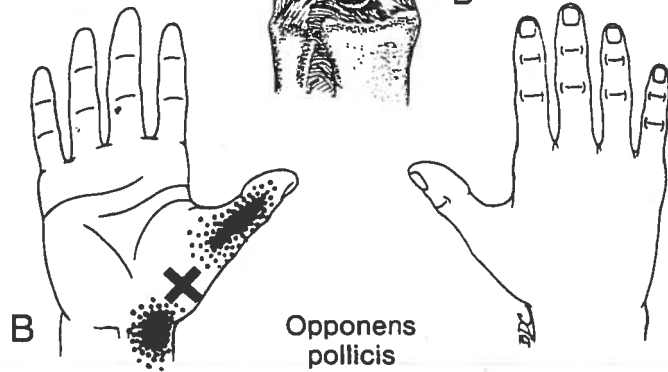
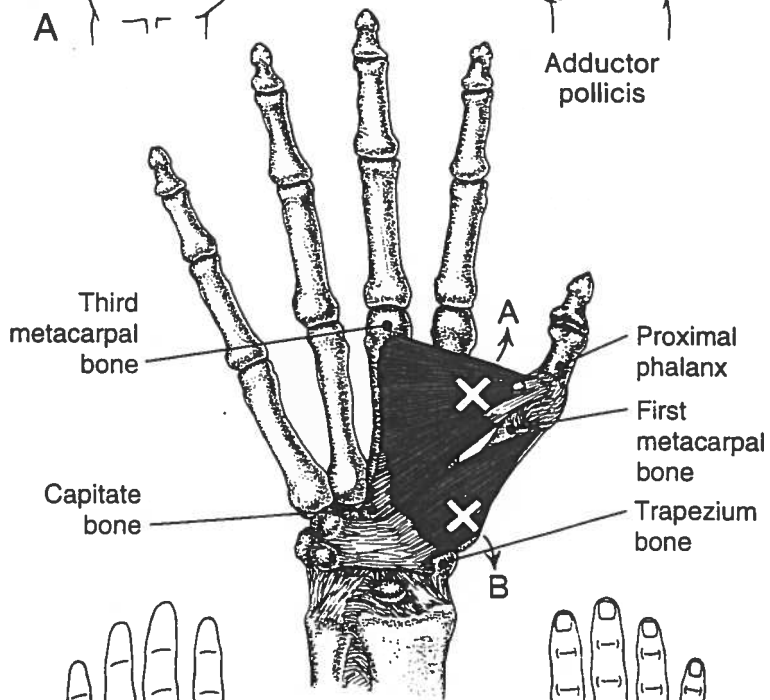
Palmaris longus (37)
Pronator teres (38)
Serratus anterior (46)
Triceps brachii (TrP₃) (32)

VOLAR WRIST AND PALMAR PAIN

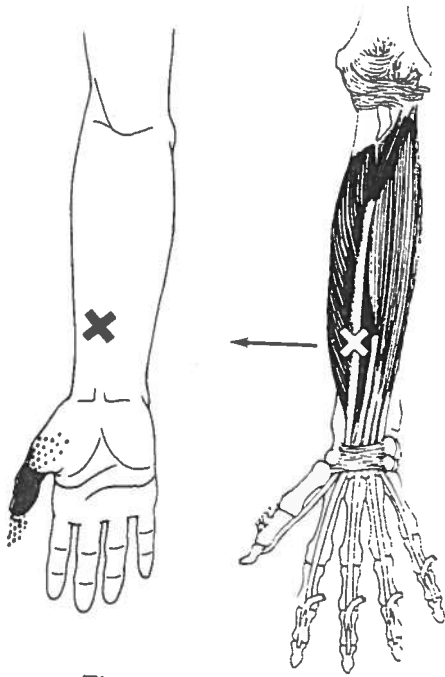
Flexor carpi radialis (38)
Flexor carpi ulnaris (38)
Opponens pollicis (39)
Pectoralis major (42)
Pectoralis minor (43)
Latissimus dorsi (24)
Palmaris longus (37)
Pronator teres (38)
Serratus anterior (46)



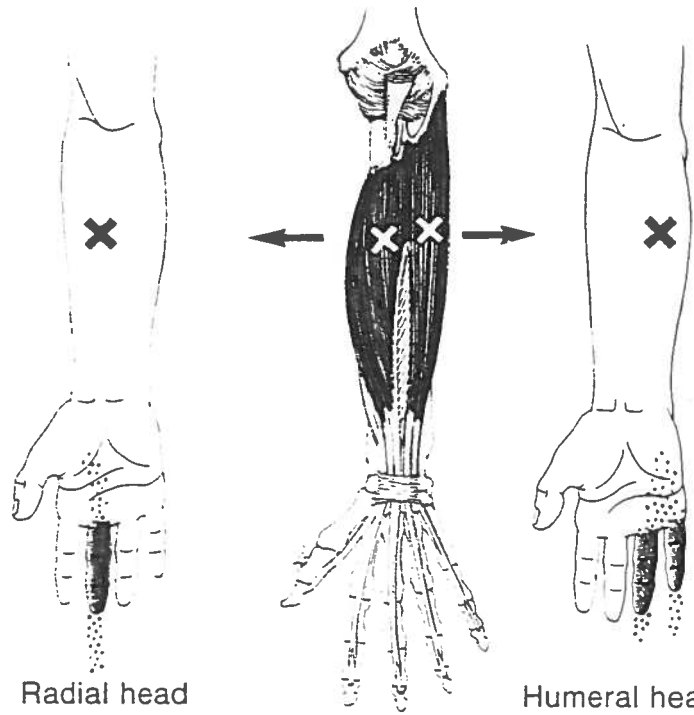
Adductor pollicis



Opponens pollicis



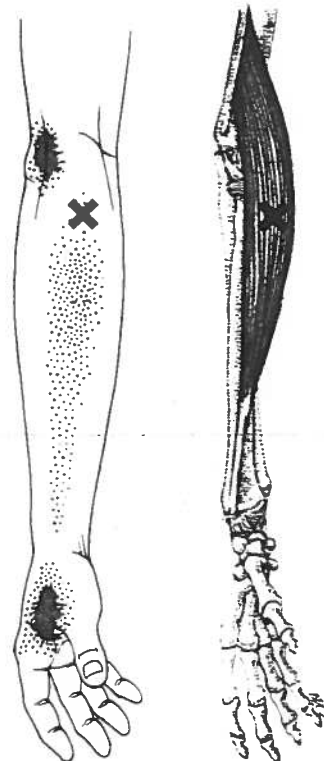
Flexor pollicis longus



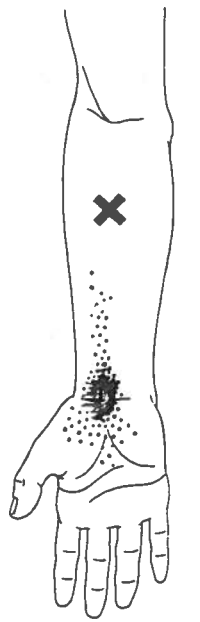Radial head

Humeral head

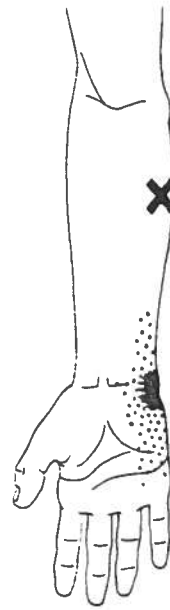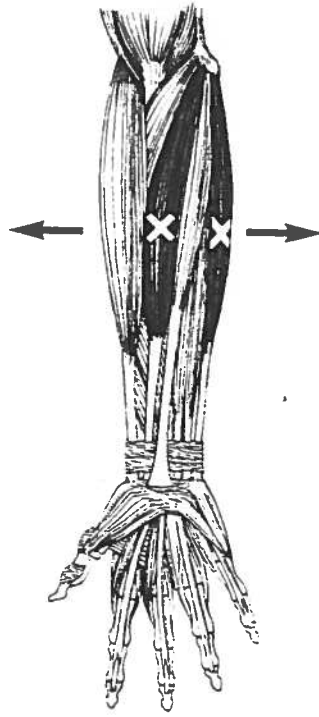
Flexor digitorum superficialis and profundus



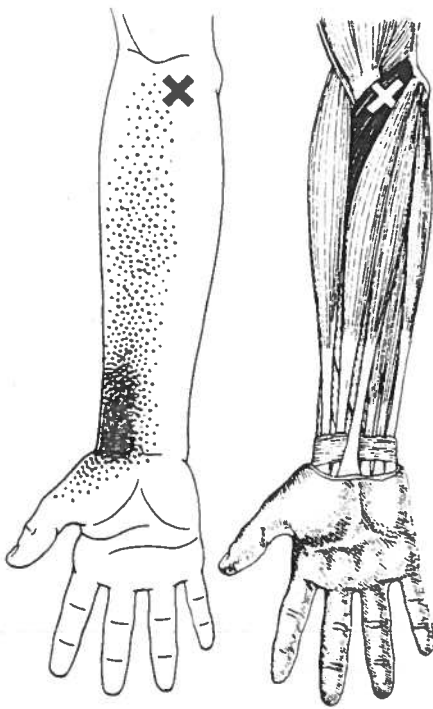
Brachioradialis



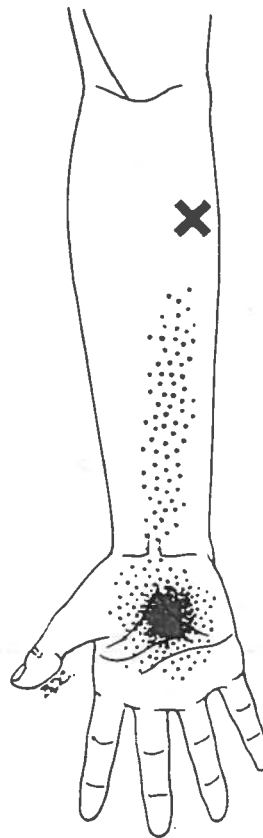
Flexor carpi radialis



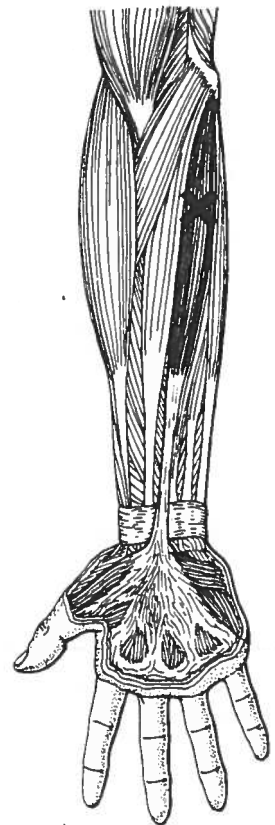Flexor carpi ulnaris

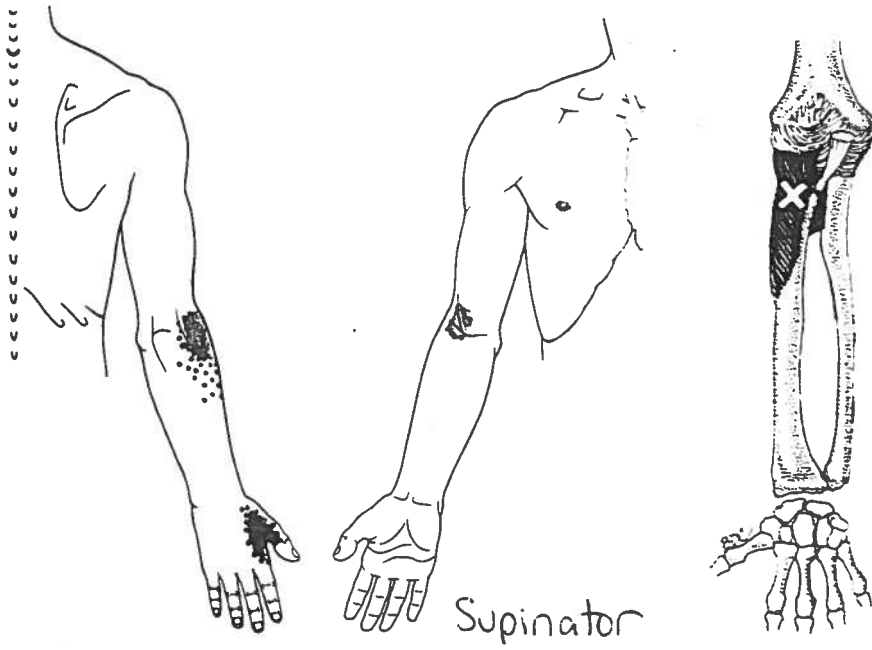


Pronator teres

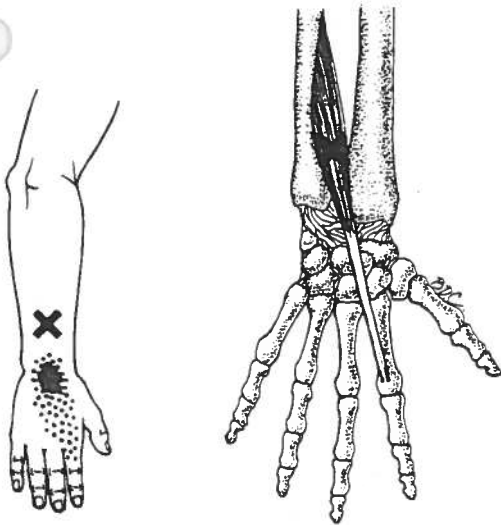


Palmaris Longus

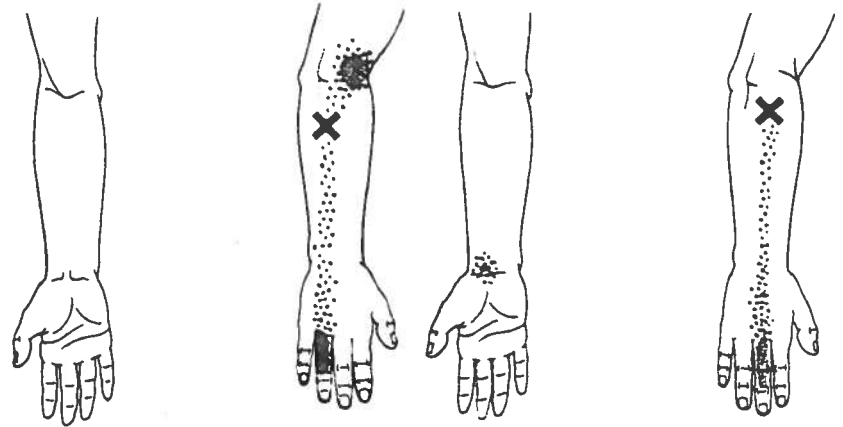




Supinator



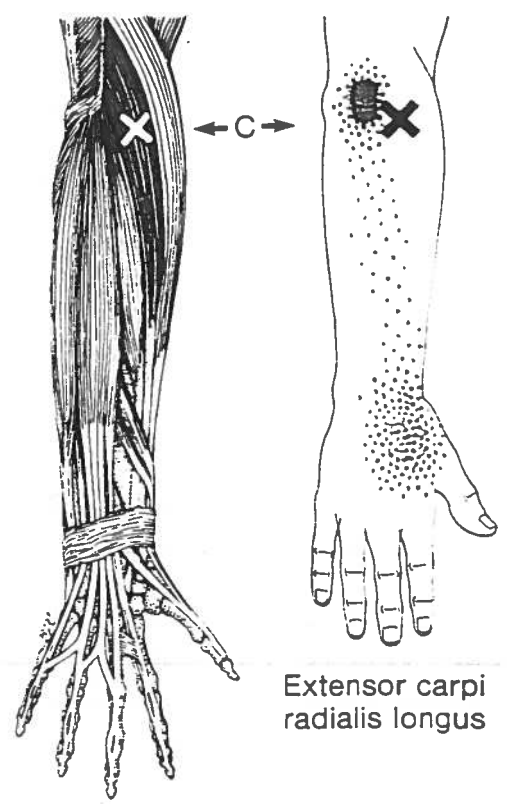
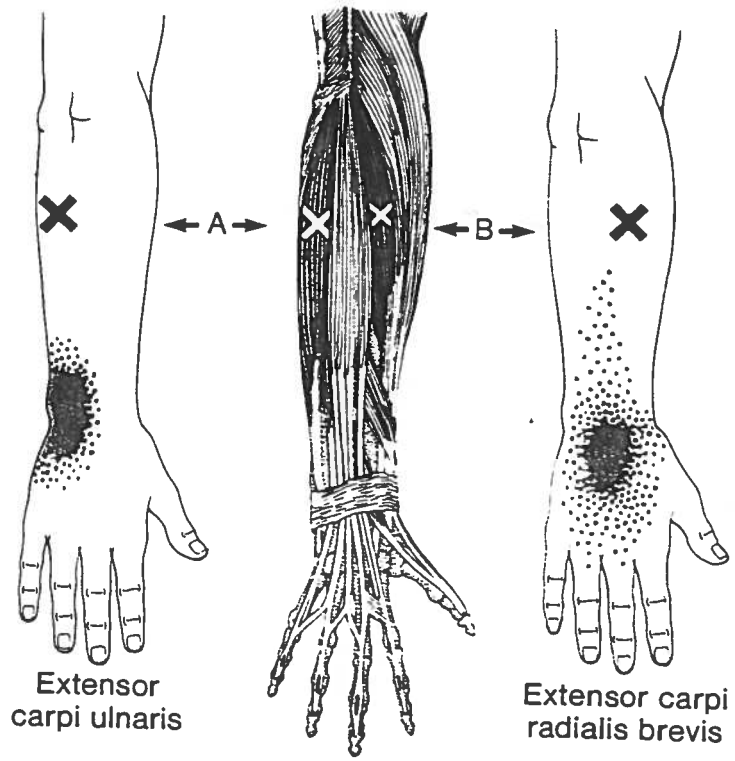
Extensor indicis

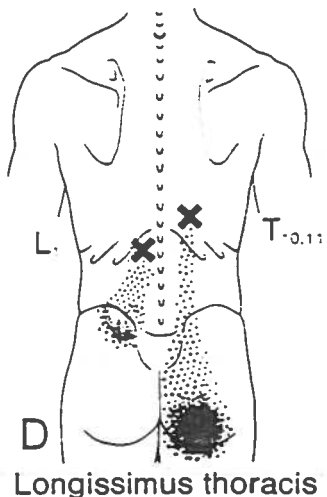
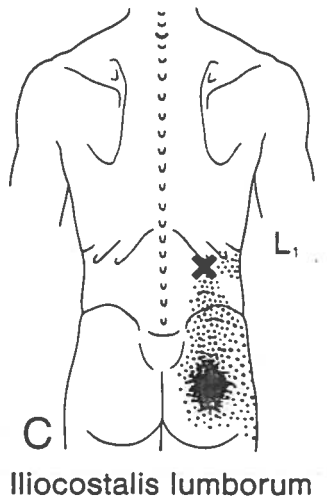
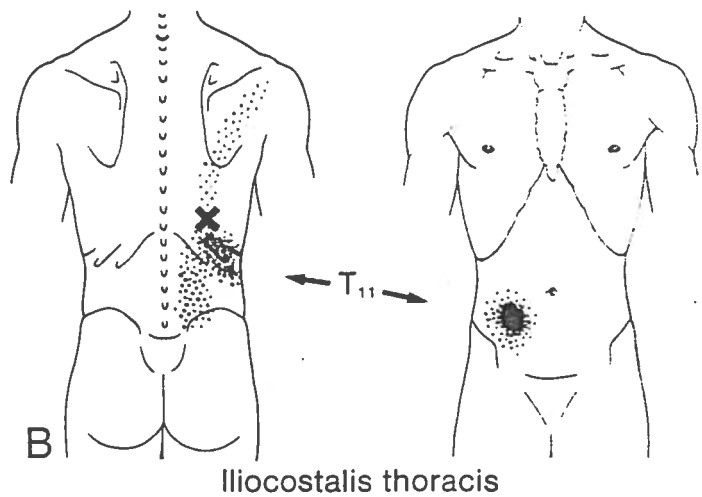
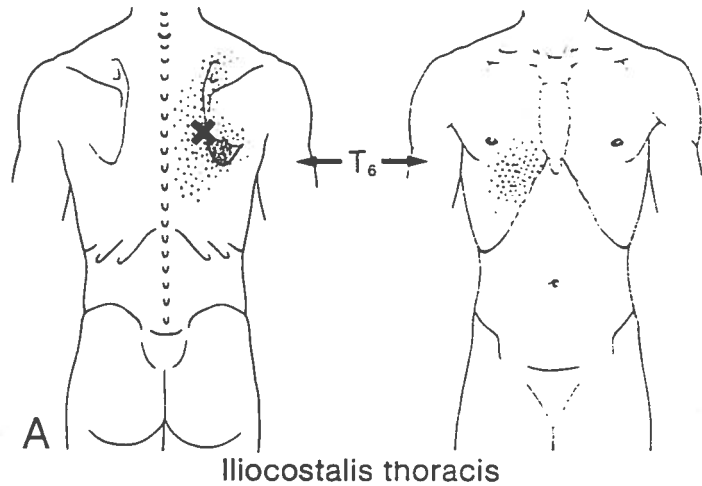


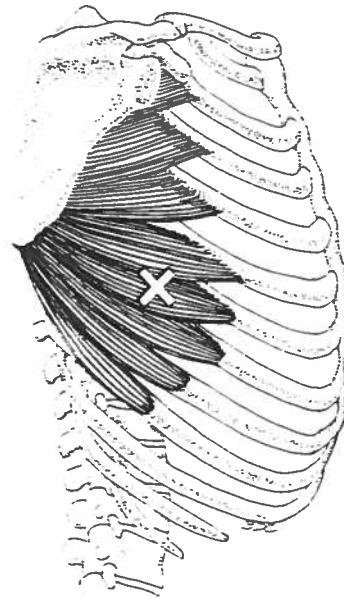
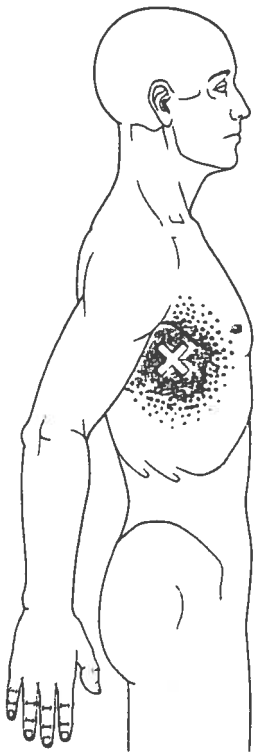
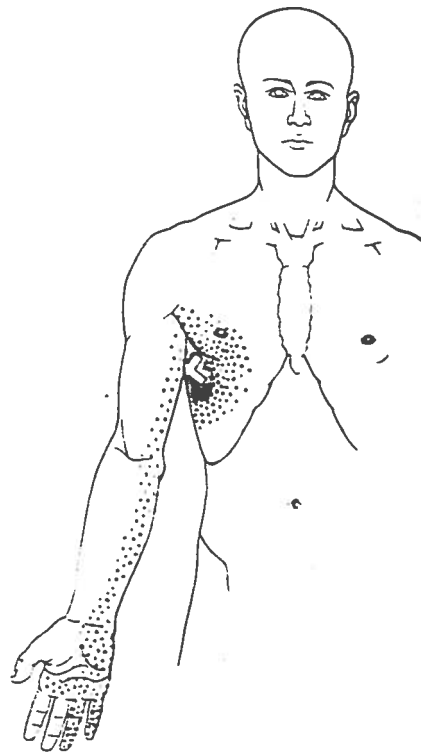
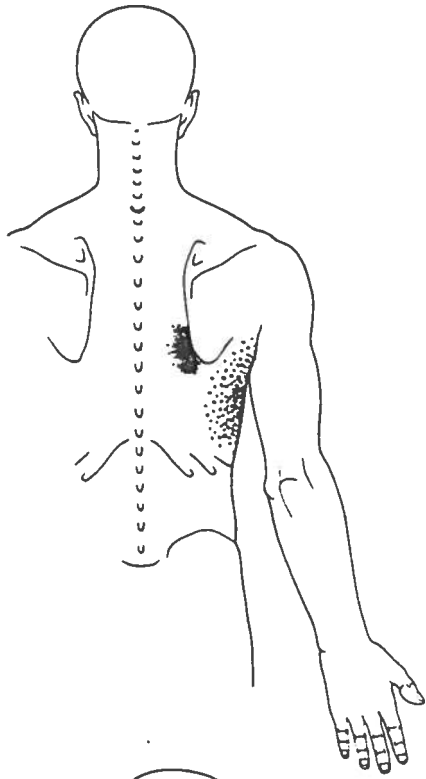
Ring finger extensor

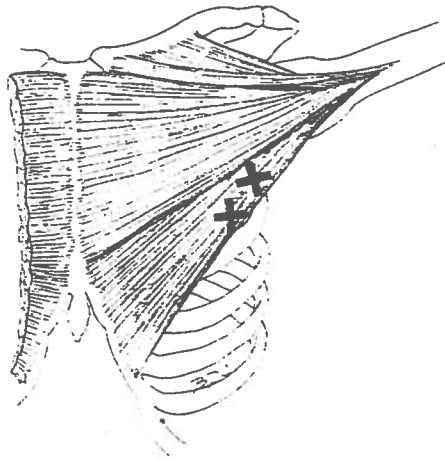
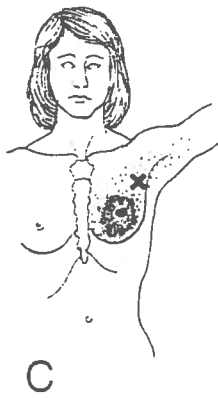
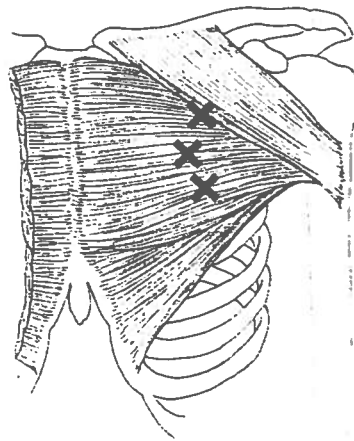
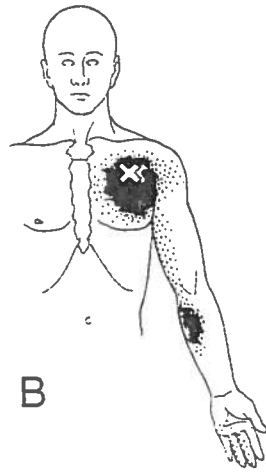
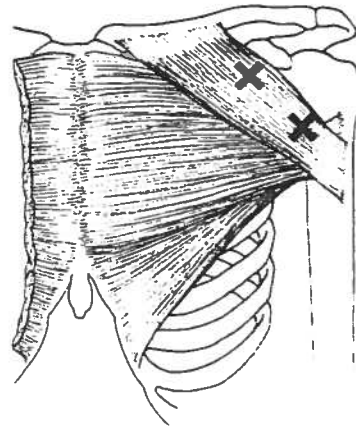
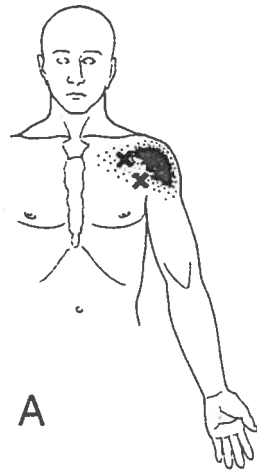
Middle finger extensor

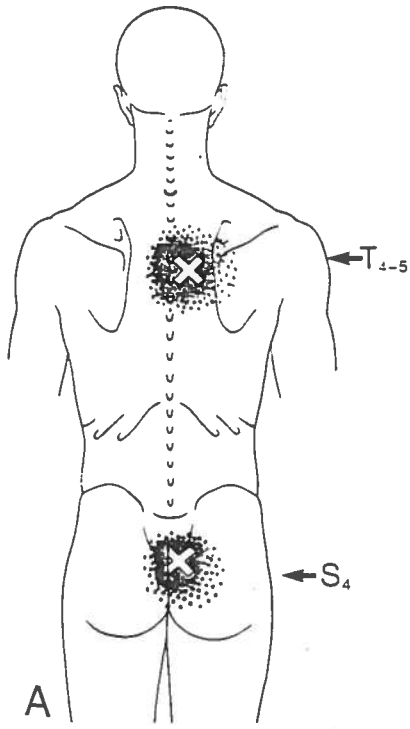
Extensor Digitorum



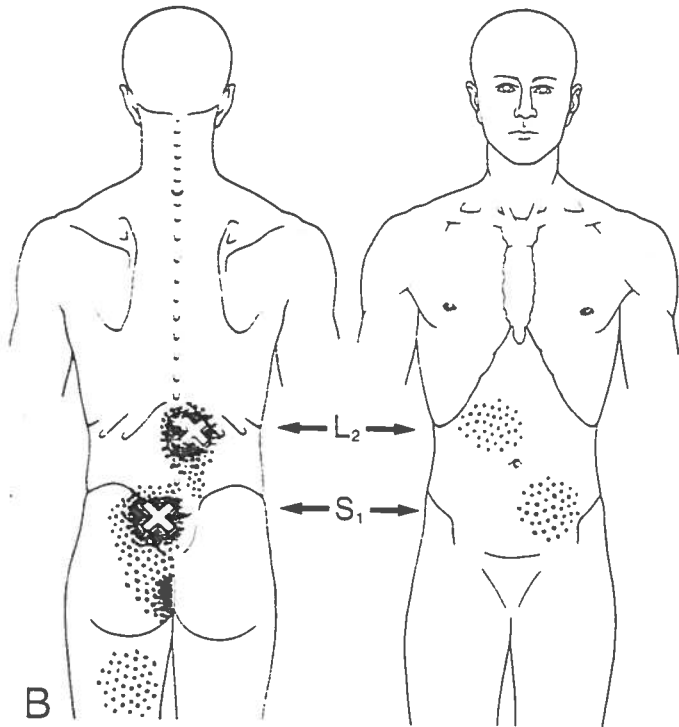




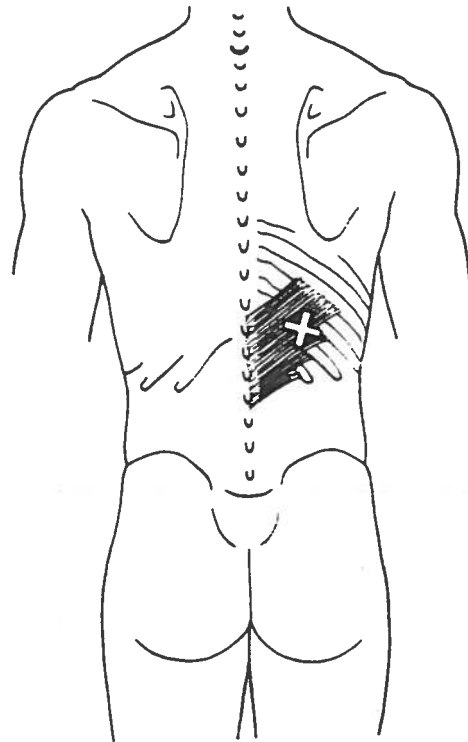
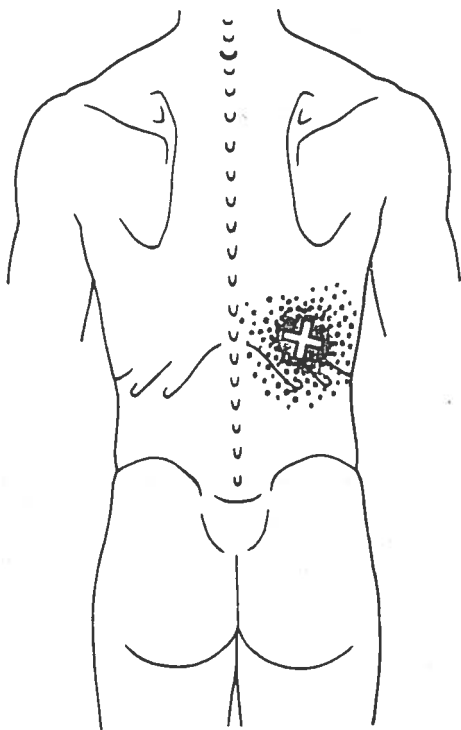
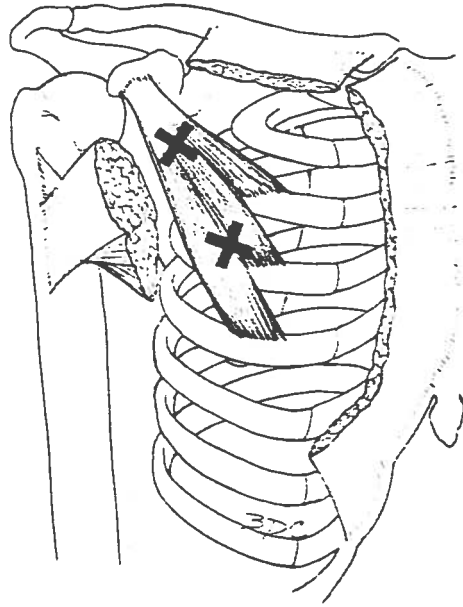
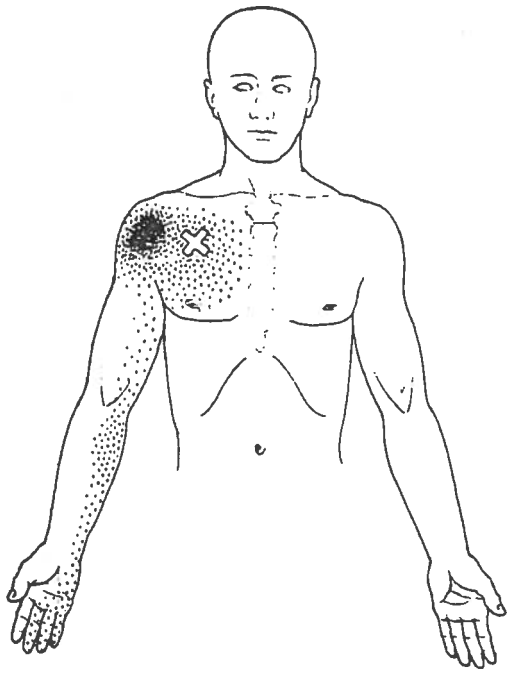


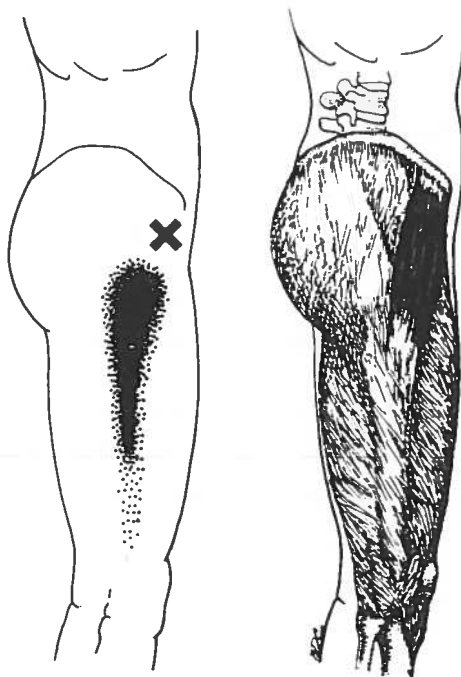
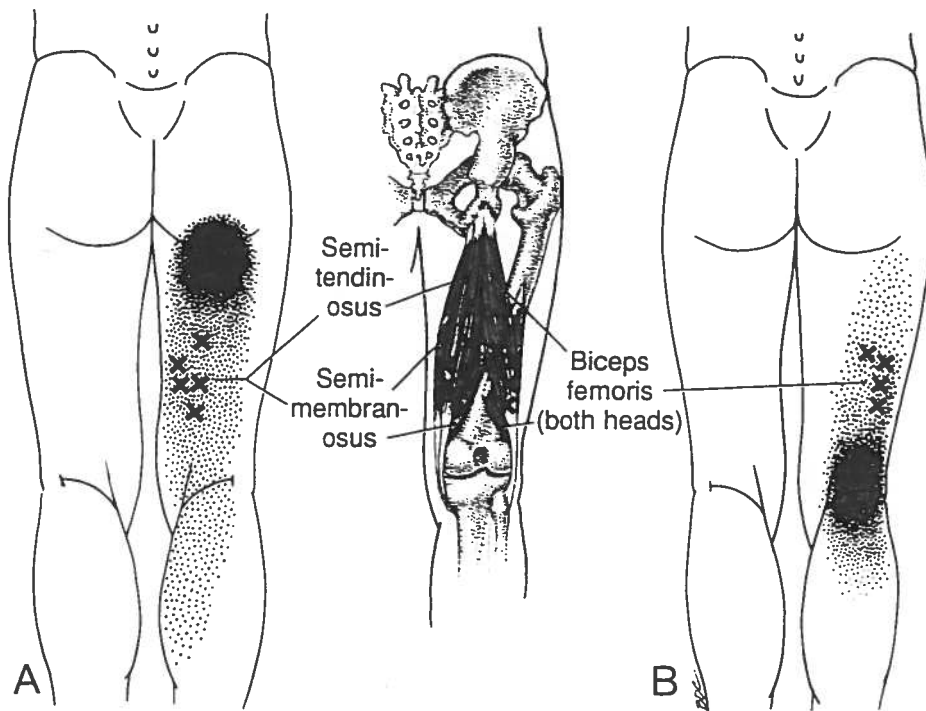


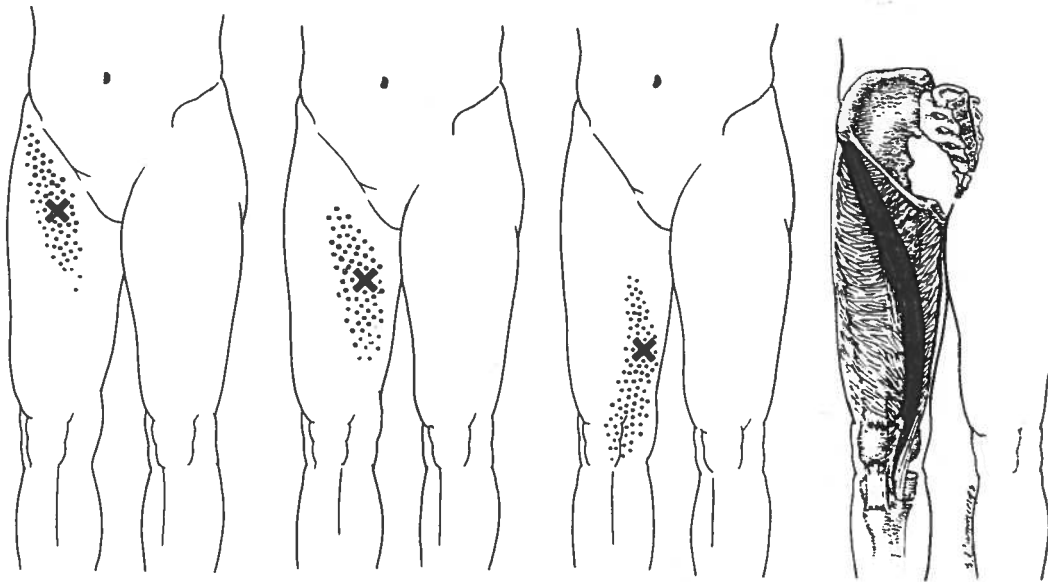
Multifidi and rotatores



Multifidi







Upper trigger point

Middle trigger point

Lower trigger point

